

# Outcome of Primary Management of Scleral Rupture without Vitrectomy Jakarta Eye Trauma Study

*by Gilbert Ws Simanjuntak*

---

**Submission date:** 28-Feb-2023 01:25PM (UTC+0700)

**Submission ID:** 2025077149

**File name:** e187436412207220-2.pdf (385.55K)

**Word count:** 3933

**Character count:** 20855



# The Open Ophthalmology Journal

Content list available at: <https://openophthalmologyjournal.com>



## RESEARCH ARTICLE

### Outcome of Primary Management of Scleral Rupture without Vitrectomy Jakarta Eye Trauma Study

Gilbert W.S Simanjuntak<sup>1,2</sup>, Biju Raju<sup>3</sup>, Golda A.M Simanjuntak<sup>1</sup> and Reinne Natali<sup>1\*</sup>

<sup>1</sup>Department of Ophthalmology, Faculty of Medicine, Christian University of Indonesia, Jakarta, Indonesia

<sup>2</sup>Cikini Eye Institute/Cikini CCI Hospital, Jakarta, Indonesia

<sup>3</sup>Dr. NSD Raju's Eye Hospital and Research Centre, Kerala, India

#### Abstract:

##### Introduction:

To report the outcome of primary management of scleral rupture without vitrectomy.

##### Methods:

Descriptive retrospective study of primary surgical management of scleral rupture located anterior to the equator. Initial and final visual acuity (FVA, intra ocular pressure, type of injury (sharp/blunt/projectile), wound length, time interval between the incident and primary repair and cause of injury were recorded. Encircling scleral buckle was placed in case of scleral laceration reaching muscle insertion. Patients who had a follow up of 3 months after the primary repair were included in the study .

##### Results:

There were 41 patients out of 78 who had scleral rupture anterior to the equator. The average age was  $21.27 \pm 9.73$  years (range 3-50 years). Thirty-three (80.4%) were males and eight (19.6%) were females. Rupture was located superiorly in 28 (68.3%) patients, and inferiorly in 13 (31.7%) patients. Eight patients underwent encircling buckle. The time interval from the injury till the primary repair less than 8 hours ( $p$  0.000) and 8-24 hours ( $p$  0.000) were associated significantly with FVA improvements. Initial VA correlated with FVA improvement significantly ( $p$  0.001). Two patients with initial VA of LP became NLP, and they had a wound length 11 mm and 12 mm respectively.

##### Conclusion:

The primary management of scleral rupture anterior to the equator, without vitrectomy, improves VA significantly. Time interval less than 24 hours and shorter wound length correlated with significant improvement of final VA.

**Keywords:** Scleral rupture, Wound size, Injury, Vitrectomy, Time interval, Equator.

#### Article History

Received: August 26, 2021

Revised: January 18, 2022

Accepted: February 23, 2022

## 1. INTRODUCTION

Open globe injury is a common cause of unilateral visual loss in the 20-45 years age group. Physical injuries to the eyes and periocular structures include lacerations, abrasions, foreign bodies, and open globe injuries, and can range from minor irritation to visual deterioration. Because they are in the productive age group, it's important to manage visual impairment of open-globe injury properly. In a large study that included 5964 eyes out of 5799 patients, the average age was

35.5±21.8 years with a male-to-female ratio of 2.8:1. The most common age was in the 45-59 years age group [1]. Causalities of injury vary between each report and geographic area, but are mostly related to work, traffic accidents, playing/gaming, and others [1 - 5]. None of these studies focus on scleral rupture anterior to equator, which has a better prognosis compared to posterior sclera rupture.

The visual outcome varies between each report [1, 2, 6]. Severe open globe injury with a retained intraocular foreign body was associated with significant visual loss [7]. Familiarity with the various types of ocular and periocular injuries is important for all medical professionals and is critical to provide the most appropriate management [8].

\* Address correspondence to this author at the Department of Ophthalmology Faculty of Medicine, Christian University of Indonesia, Jalan PS Sutoyo, Cawang, Jakarta, Indonesia; Tel: +62-21-80870762; Fax: +62-21-38997778; Mobile: +62-811168237; E-mail: [retinaid@yahoo.com](mailto:retinaid@yahoo.com)

It is important to clearly delineate the characteristics of patients who sustain open globe injuries anterior to the equator only, to better understand the associated factors related to visual outcome improvement and to ensure proper care. This study aimed to report the outcome of sclera tears anterior to the equator managed primarily without vitrectomy.

## 2. METHODS

This is a descriptive retrospective study done by collecting patients' medical records with primary surgical management for scleral rupture, in a tertiary hospital in Jakarta from September 2018 to August 2020. The Christian University of Indonesia Institutional Ethics Committee approved this study following the tenets of the Declaration of Helsinki.

Slit lamp examination was done carefully to look for any significant anterior segment findings (conjunctiva tear, hyphema, afferent pupillary defect, and depth of anterior chamber). Initial and final Visual Acuity (VA) (improvement if final VA gains 2 lines or more), eye movement, intraocular pressure, type of injury (sharp/blunt/projectile), wound length, and cause of injury were recorded. If there were media opacities (severe corneal edema, cataract and/or vitreous hemorrhage) and suspicion of intraocular foreign body, a B-scan examination was done with minimal pressure to the eyeball and/or an orbital X-ray. Time intervals between injury, surgical management and follow-up duration were also recorded. Cases of scleral rupture anterior to the equator were included in this study. Cases with corneal rupture without scleral rupture or scleral rupture reaching the equator or/and extended posterior to the equator were excluded.

Surgical management was done under general anesthesia once the patient was fit for surgery. Conjunctiva was incised to explore the length of scleral rupture. End-to-end length of the sclera rupture was measured using a caliper. Sclera and conjunctiva were sutured with 8.0 Vicryl. An encircling scleral buckle was placed if the scleral rupture extended posteriorly to the muscle insertion. All procedures were done after obtaining a thorough informed consent, including possibilities of evisceration or enucleation.

During the preparation for surgery, the eye was patched. Systemic Gentamycin was given intravenously and topical Gentamycin eye drops were instilled hourly in the affected eye. After surgery, the systemic antibiotic was continued for three days, and topical antibiotics along with topical steroids (Prednisolone Acetate) were started and gradually tapered off. Patients who completed the 3 months follow-up visit were included in the analysis. SPSS version 24.0 (SPSS, Inc.,

Chicago, IL) was used for all statistical analyses, and  $P < 0.05$  was considered significant.

## 3. RESULTS

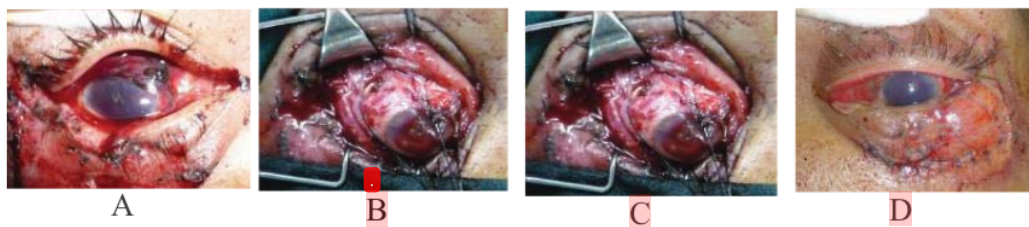
Among the 78 patients with scleral rupture, 30 patients were excluded as the tear extended posteriorly to the equator. None of the patients had a history of previous eye surgeries. 7 patients refused surgery. 41 eligible patients had scleral rupture not reaching the equator during surgical exploration; 33 (80.4%) male and 8 (19.6%) female. There were 25 (60.97%) patients with cornea-sclera wounds. None of the eligible subjects had a retinal detachment.

The average age was  $21.27 \pm 9.73$  years (range 3-50 years), and a total of 75.5% were aged 11-30 years. A total of 64.4% presented with initial visual acuity of less than 3/60. Blunt trauma was the cause of scleral rupture in 53.6% of cases, 43.2% due to sharp force trauma, and 12.3% from projectile trauma. The incidence of trauma at home was 43.9%, a more frequent occurrence than in other places, trauma in the workplace 29.3%, and from traffic accidents 26.8%. The incident in the workplace was in 58.3% due to fights/assault.

B-scan ultrasonography was carried out in 17 (41.5%) of cases with obscured optical media and showed vitreous hemorrhage in nine cases (21.9%) and subretinal hemorrhage in two cases (4.9%). In 37 (90.2%) cases with a suspected orbital fracture, X-ray examination was done but was negative.

After conjunctival incision and wound exploration, the scleral rupture was seen superiorly (medial or temporal) in 28 (68.3%) patients, and inferiorly (medial or temporal) in 13 (31.7%) patients. Eight patients underwent encircling buckle, as the rupture extended posteriorly to muscle insertion. Cataract extraction was done in 15 cases. Wound length varied between 2-12 mm and the shape of the wound was mostly irregular. Wound length significantly correlated with improved final VA ( $p$  0.01, CI 0.009 – 0.015). None of the cases underwent vitrectomy at the time of primary repair (Fig. 1).

Twenty-two patients (53.6%) underwent surgery less than 8 hours after the injury occurred, 15 (36.6%) underwent surgery 8 to 24 hours after the injury, and 4 (12.2%) were operated on more than 24 hours after the injury. Most of the patients came to the hospital less than 24 hours after injury (90%). Time interval (less than 8 hours and 8-24 hours) from the incident till the primary repair was associated significantly with final VA improvements ( $p$  0.000 and 0.000 respectively). The average follow-up of patients was 23 weeks (range 12 – 43 weeks).



**Fig. (1).** A. Pre-operative photograph, B and C. During primary repair, the wound found to be anterior to the equator but passing through muscle insertion, and therefore a buckle was placed. D. postoperative picture after primary repair of the scleral tear and eye lid laceration.

Initial VA was  $0.12 \pm 0.249$  and final VA was  $0.23 \pm 0.314$  and improvement in Visual Acuity (VA) was statistically significant ( $p < 0.001$ ). There were 29 (70.8%) patients presenting with 6/60 or worse, and 9 (21.9%) patients with VA 6/6 to 6/60. Three (7.3%) patients presented with No Light Perception (NLP) their time to present to the emergency room varied from < 8 to 24 hours and the wound length varied from 2 to >10 mm. Two patients with initial VA of LP had an unfavorable outcome after primary repair with a final visual acuity of NLP. These 2 patients had a larger wound length - 11 mm and 12 mm respectively. In the final VA distribution, there were 21 (51.2%) patients with VA 6/60 or worse and 19 (46.3%) patients with VA 6/6 - 6/60. Presenting clinical characteristics, wound size and interval between the time of injury to surgical intervention are shown in Table 1.

**Table 1. Clinical characteristic, wound length and interval between time of injury to surgical intervention.**

Presenting Clinical Characteristic	n	%
- Reduced VA	39	95
- Decreased IOP	30	73.2
- Hyphema	25	61
- Conjunctival chemosis	10	24.4
- Conjunctival rupture	31	75.6
- Traumatic cataract	3	7
Initial Visual Acuity		
- 6/12 or better	3	7.3
- 6/15 to 6/60	6	14.6
- 6/60 or worse	29	70.8
- No light perception	3	7.3
Wound length		
- Less than 3 mm	11	26.8
- 3 -5 mm	19	46.3
- 6 -9 mm	6	14.6
- More than 10 mm	5	12.3
Interval between injury and surgery		
- Less than 8 hours	22	53.6
- 8 - 24 hours	15	36.6
- More than 24 hours	4	9.8

**4. DISCUSSION**

Serious eye injury is common in clinical practice, often causing great damage to visual function, resulting in poor visual and anatomic outcomes despite surgical intervention [9]. Scleral rupture is more common at younger age and mostly occurs among males. In this study, most patients were between the ages of 11-30 years (75.5%), the average age was 36 years and 84% were male. Male predominance is a universal characteristic and has been demonstrated in several studies in different countries [1, 5, 7, 10].

In this study, the domestic accident was found in almost half of the total patients, followed by the workplace accident. Though similar findings were reported from Malaysia, workplace-related injuries accounted for most of the ocular injuries (41.4%), followed by motor vehicle accidents (25.7%), domestic accidents (22.4%), assault (7.9%), sports accidents (2.0%), and school-related accidents (0.6%). In their study 39

patients (25.7%) sustained injuries associated with organic matter, and none were found in our subjects [11].

A thorough initial examination helps in the formulation of the primary management plan and to determine the prognosis. The open globe injury prognostic model demonstrated predictive accuracy and can be useful in counseling patients and making clinical decisions regarding open globe injury management [12]. Several other prognostic methods are also available such as the Ocular Trauma Classification Group, Regression tree analysis, and methods that perform intraocular cultures on open globes injury [12 - 14]. The Ocular Trauma Study (OTS) group evaluated more than 2500 ocular injuries associated with non-combat causes and formulate a methodology to predict the final visual outcome at the time of initial injury [15]. Whenever the eyeball cannot be salvaged on the operating table, evisceration or primary enucleation was performed [16]. In this study, thorough informed consent was obtained from all the patients, but none underwent evisceration or primary enucleation.

Initial visual acuity of NLP after ocular trauma does not mean permanent visual loss as reported in the past. Even in severe eyeball laceration, early intervention of vitrectomy combined with silicone oil tamponade to achieve retinal reattachment may make the severely traumatized eyes regain the VA of LP or better. Unfortunately, three eyes in our series that presented with NLP did not improve after primary management.

Though vitrectomy was not part of the primary repair in this case series, Vitrectomy was still needed in cases of non-clearing vitreous hemorrhage as seen in several cases. The timing to do vitrectomy is debatable; some surgeons prefer to do it between 10 - 14 days; waiting for vitreous detachment can simplify the surgical procedure.

At presentation, 95% of patients had decreased VA and 73.2% of patients had decreased IOP. The most common cause of a decreased VA in eye trauma was myopic shift due to lens thickening and anterior chamber shallowing, which recovers spontaneously as time passes. Therefore, conservative management would be a good choice for managing eyes with blunt trauma in an emergency department, especially when there is no suspicion of eyeball rupture [17 - 22]. In this study, the initial VA was mostly below 6/60 (70.8%) and there were three cases (7.3%) with NLP vision. The defective vision was either due to the structural damage to the anterior segment including hyphema in 25 cases (61%), and traumatic cataract in 3 cases (7%); or because of posterior segment disorders such as vitreous hemorrhage in 9 cases (21.9%), and subretinal bleeding in 2 cases (4.9%). Other notable clinical presentations were the presence of conjunctival chemosis (24.4%) and conjunctival rupture (75.6%).

By the ocular ancillary examination, there were 21.9% of patients with vitreous hemorrhage, without intraocular foreign body. Other studies showed that the presence of intraocular foreign body and retinal detachment are poor prognostic indicators [10, 12]. Although the presence of an IOFB alone was not a statistically significant prognostic factor, retained IOFB in combination with posttraumatic endophthalmitis was

associated with a particularly poor visual outcome [14, 22 - 24].

In this study, 73.1% of cases had a wound size of 5 mm or less. This was similar to zone II the Ocular Trauma Classification Group and was related to a better prognosis than zone 3. Zone 3 injuries involved full-thickness scleral defects more than 5 mm posterior from the limbus. The wound location and size described the extent of damaged tissue and were associated with the prognosis [3, 7, 12]. There were two cases with 11-12 mm wide wounds that came with LP vision that became NLP after the primary management. Wounds that are longer than 10 mm for example, even if did not reach the rectus muscle insertion, can be a poor prognostic factor. The possibility of giving steroids to suppress the inflammation may be considered, in order to prevent total blindness and phthisical eye in such eyes.

In this study, the interval between injury and surgery was less than 8 hours in 53.6% of cases. Some studies suggested that the delay in primary repair increases the risk of post-traumatic endophthalmitis. Studies on post-traumatic endophthalmitis showed the following as protective factors: early primary repair, intraocular tissue prolapse, and self-sealing wound [1, 11, 14]. There were 4 cases (9.8%) who underwent surgery after more than 24 hours, but none had endophthalmitis. The incidence of endophthalmitis can be reduced by the administration of intravenous antibiotics before surgery [15, 21]. Sympathetic ophthalmia (SO), which is a devastating, though uncommon, bilateral granulomatous panuveitis following uveal trauma to one eye. The prevalence of SO after eye injury is estimated to be between 0.1% and 0.3%. Due to its very low incidence, it is controversial whether SO can be prevented by removing the eye after trauma. The prevention of SO by evisceration or enucleation is controversial [20, 22, 25].

In the setting of a severely ruptured or lacerated globe with gross prolapse and/or loss of retinal and uveal tissue, primary enucleation is a valid alternative to primary repair with anticipated secondary enucleation. Considerations include the status of the fellow eye, the opportunity for patient and/or family counseling and consent, and the patient's medical status [15, 18, 19, 25].

## CONCLUSION

In conclusion, the primary management of scleral rupture anterior to the equator without vitrectomy provides favorable visual outcomes. The interval from injury to the treatment of less than 24 hours and initial VA are statistically significant factors for VA improvement.

## LIST OF ABBREVIATIONS

VA	=	Visual Acuity
OTS	=	Ocular Trauma Study

## ETHICS APPROVAL AND CONSENT TO PARTICIPATE

The Christian University of Indonesia Institutional Ethics Committee granted approval for this study.

## HUMAN AND ANIMAL RIGHTS

No animals were used for studies that are the basis of this research. All the humans used were in accordance with the Helsinki Declaration of 1975.

## CONSENT FOR PUBLICATION

Informed consent has been obtained from the participants involved.

## STANDARDS OF REPORTING

STROBE guidelines were followed.

## AVAILABILITY OF DATA AND MATERIALS

Not applicable.

## FUNDING

None.

## CONFLICT OF INTEREST

The author declares no conflict of interest, financial or otherwise.

## ACKNOWLEDGEMENTS

Declared none.

## REFERENCES

- Qi Y, Zhang FY, Peng GH, et al. Characteristics and visual outcomes of patients hospitalized for ocular trauma in central China: 2006-2011. *Int J Ophthalmol* 2015; 8(1): 162-8. [PMID: 25709927]
- Gendler S, Nadler R, Erlich T, Fogel O, Shushan G, Glassberg E. Eye injury in the Israeli Defense Force: "An ounce of prevention is worth a pound of cure". *Injury* 2015; 46(7): 1241-4. [http://dx.doi.org/10.1016/j.injury.2015.01.035] [PMID: 25682313]
- Erickson BP, Cavuoto K, Rachitskaya A. Zone 3 ruptured globe from a dog bite. *J AAPOS* 2015; 19(1): 89-90. [http://dx.doi.org/10.1016/j.jaapos.2014.09.011] [PMID: 25727600]
- Menon KV, Al Rawi AE, Taif S, Al Ghafri K, Mollahalli KK. Orbital roof fracture and orbital cellulitis secondary to halo pin penetration: case report. *Global Spine J* 2015; 5(1): 63-7. [http://dx.doi.org/10.1055/s-0034-1384818] [PMID: 25648519]
- Chakraborti C, Giri D, Choudhury K, Mondal M, Datta J. Paediatric ocular trauma in a tertiary eye care center in Eastern India. *Indian J Public Health* 2014; 58(4): 278-80. [http://dx.doi.org/10.4103/0019-557X.146297] [PMID: 25491522]
- Desai P, Morris DS, Minassian DC, MacEwen CJ. Trends in serious ocular trauma in Scotland. *Eye (Lond)* 2015; 29(5): 611-8. [http://dx.doi.org/10.1038/eye.2015.7] [PMID: 25679414]
- Sharma AK, Shah DN, Shrestha JK, Thapa M, Shrestha GS. Ocular injuries in the people's uprising of April 2006 in Kathmandu, Nepal. *Nepal J Ophthalmol* 2014; 6(1): 71-9. [http://dx.doi.org/10.3126/nepjoph.v6i1.10775] [PMID: 25341829]
- Pargament JM, Armenia J, Nerad JA. Physical and chemical injuries to eyes and eyelids. *Clin Dermatol* 2015; 33(2): 234-7. [http://dx.doi.org/10.1016/j.clindermatol.2014.10.015] [PMID: 25704943]
- Yang SS, Jiang T. Vitrectomy combined with silicone oil tamponade in the treatment of severely traumatized eyes with the visual acuity of no light perception. *Int J Ophthalmol* 2013; 6(2): 198-203. [PMID: 23638424]
- Casson RJ, Walker JC, Newland HS. Four-year review of open eye injuries at the Royal Adelaide Hospital. *Clin Exp Ophthalmol* 2002; 30(1): 15-8. [http://dx.doi.org/10.1046/j.1442-9071.2002.00484.x] [PMID: 11885788]
- Hooi SH, Hooi ST. Open-globe injuries: the experience at Hospital

- Sultanah Aminah, Johor Bahru. Med J Malaysia 2003; 58(3): 405-12. [PMID: 14750381]
- [12] Schmidt GW, Broman AT, Hindman HB, Grant MP. Vision survival after open globe injury predicted by classification and regression tree analysis. *Ophthalmology* 2008; 115(1): 202-9. [http://dx.doi.org/10.1016/j.ophtha.2007.04.008] [PMID: 17588667]
- [13] Knyazer B, Bilenko N, Levy J, *et al.* Open globe eye injury characteristics and prognostic factors in southern Israel: a retrospective epidemiologic review of 10 years experience. *Isr Med Assoc J* 2013; 15(3): 158-62. [PMID: 23662378]
- [14] Lieb DF, Scott IU, Flynn HW Jr, Miller D, Feuer WJ. Open globe injuries with positive intraocular cultures. *Ophthalmology* 2003; 110(8): 1560-6. [http://dx.doi.org/10.1016/S0161-6420(03)00497-4] [PMID: 12917173]
- [15] Kuhn F, Morris R, Witherspoon C. Birmingham Eye Trauma Terminology (BETT): terminology and classification of mechanical eye injuries. *Ophthalmol Clin North Am* 2002; 15(2): 139-143, v. [http://dx.doi.org/10.1016/S0896-1549(02)00004-4] [PMID: 12229228]
- [16] Dahr SS, McCulley TJ, Kersten RC, Schneider SS, Hutchins RK. Decision factors for primary enucleation in a trauma setting: a clinicopathologic study. *Invest Ophthalmol Vis Sci* 2003; 44: 822.
- [17] Kim JJ, Moon JH, Jeong HS, Chi M. Has decreased visual acuity associated with blunt trauma at the emergency department recovered? *J Craniofac Surg* 2012; 23(3): 630-3. [http://dx.doi.org/10.1097/SCS.0b013e31824db77a] [PMID: 22565865]
- [18] Moreno L, Velasquez LF, Restrepo CA, *et al.* Ocular trauma from land mines among soldiers treated at a University Hospital in Medellín, Colombia. *Colomb Med (Cali)* 2013; 44(4): 218-23. [http://dx.doi.org/10.25100/cm.v44i4.1356] [PMID: 24892238]
- [19] Meng Y, Yan H. Prognostic factors for open globe injuries and correlation of ocular trauma score in Tianjin, China. *J Ophthalmol* 2015; 2015: 1-6. [http://dx.doi.org/10.1155/2015/345764] [PMID: 26491549]
- [20] Chronopoulos A, Ong JM, Thumann G, Schutz JS. Occult globe rupture: Diagnostic and treatment challenge. *Surv Ophthalmol* 2018; 63(5): 694-9. [http://dx.doi.org/10.1016/j.survophthal.2018.04.001] [PMID: 29649485]
- [21] Jousen AM, Müller B, Kirchhof B, Stappler T, Zeitz O. Rupture of the globe: What to do, what not to do. *Klin Monatsbl Augenheilkd* 2020; 237(9): 1070-8. [http://dx.doi.org/10.1055/a-1233-8997] [PMID: 32967031]
- [22] Fujikawa A, Mohamed YH, Kinoshita H, *et al.* Visual outcomes and prognostic factors in open-globe injuries. *BMC Ophthalmol* 2018; 18(1): 138. [http://dx.doi.org/10.1186/s12886-018-0804-4] [PMID: 29884145]
- [23] Chauhan M, Samarah H, Al-Hindi H, Sanders R, Uwadayat S. Anatomic and visual outcomes of patients with incomplete closure of zone 3 scleral lacerations. *Invest Ophthalmol Vis Sci* 2021; 62(8): 1352.
- [24] Kanu LN, Jiang Y, Gonzalez AFV, Mieler WF. Visual and anatomic outcomes in perforating ocular injuries. *J Vitreoretin Dis* 2019; 3(6): 428-37. [http://dx.doi.org/10.1177/2474126419865992] [PMID: 31742242]
- [25] Ozturker C, Kaynak P, Karabulut G, Yildirim Y, Oacak O. Management of open globe injuries and concern about sympathetic ophthalmia: A case report. *Beyoglu Eye Journal* 2018; 3(1): 38-42. [http://dx.doi.org/10.14744/bej.2018.58066]

© 2022 Simanjuntak *et al.*

This is an open access article distributed under the terms of the Creative Commons Attribution 4.0 International Public License (CC-BY 4.0), a copy of which is available at: <https://creativecommons.org/licenses/by/4.0/legalcode>. This license permits unrestricted use, distribution, and reproduction in any medium, provided the original author and source are credited.

# Outcome of Primary Management of Scleral Rupture without Vitrectomy Jakarta Eye Trauma Study

---

## ORIGINALITY REPORT

---

14%

SIMILARITY INDEX

15%

INTERNET SOURCES

7%

PUBLICATIONS

0%

STUDENT PAPERS

---

## MATCH ALL SOURCES (ONLY SELECTED SOURCE PRINTED)

---

6%

★ zenodo.org

Internet Source

---

Exclude quotes  On

Exclude matches  < 2%

Exclude bibliography  On