



## Case series

## Severe headache and seizure free after microscopic fenestration craniotomy of middle Fossa arachnoid cyst: Case series

Robert Sinurat\*

Surgery Department, Medical Faculty of Universitas Kristen, Indonesia

## ARTICLE INFO

## Keywords:

Case series  
Arachnoid cyst  
Middle fossa  
Pressure  
Surgery  
Outcome

## ABSTRACT

**Introduction:** Arachnoid cyst in the middle fossa can cause many symptoms include headache and seizure. When drugs therapy can not relieve or control the symptoms, it is necessary to determine whether the surgical procedure can improve patient's outcome.

**Case presentation:** First case, 28 years old female suffered from severe headache and sometimes unconsciousness for a few minutes. Magnetic resonance images showed the lesion hypo-intense on T1-weight and hyper-intense on T2-weight images. Left M1 middle cerebral artery lay down inside the cyst.

The second case, a man 18 years old had seizures every three months. He took phenytoin 600 mg a day but in the last one month seizures repeated up to five times. The brain MRI results showed a hypointense lesion of T1-weight and hyperintense at T2-weight in the right temporal region measuring approximately 5 × 4 cm and compressing the temporal bone to form a convex shape.

The third case, a man 23 years old had complaints of seizures since 6 months. The patient received the drug phenytoin 3x200mg and valproic acid 1 g daily but the seizures still exist. The brain MRI showed hyperintense lesion in the right temporal region.

Microscopic fenestration craniotomy was performed in all cases and at one year of follow-up the headache disappeared. Seizure attacks have never occurred again with only low doses of phenytoin.

**Conclusion:** The result of microscopic fenestration craniotomy in patients with headaches and seizures due to middle fossa arachnoid cysts is good and can be considered for controlling seizures in selected cases.

## 1. Introduction

Arachnoid cyst is a non-neoplastic cyst formed by the arachnoid membrane and filled with cerebrospinal fluid. Primary arachnoid cyst occurs in utero because of splitting arachnoid membrane and secondary arachnoid cyst developed after head trauma, surgery, infection, or intracranial hemorrhage [1].

The incidence of arachnoid cyst varies from 1 to 2%, and Al-Holou et al. have found 1,4% of adults patient [2]. The cysts were mostly in the middle fossa and left side predominantly. Arachnoid cyst may not cause any symptoms, but if the cyst are large or in a certain location they can cause clinical symptoms. Headache is the most complaint, and the other symptom was ataxia, hearing loss, mental changes, or seizure [3]. Class I evidence of arachnoid cyst surgery is still not available. But many experts have reported the good outcome of microscopic fenestration surgery or endoscopic arachnoid cysts fenestration [4,5]. The decision for doing surgery depends on the clinical symptoms, laboratory results,

electroencephalography, and brain computerized tomography scan (ct-scan) or magnetic resonance imaging (MRI).

Not all health centers or patients can do such a completed examination due to the lack of facility, limited financial or health insurance. The author Dr.dr. Robert Sinurat, SpBS as a senior neurosurgeon in medical faculty and hospital of Universitas Kristen Indonesia has performed the surgery and reports three cases of middle fossa after microscopic fenestration craniotomy based on patient's symptom and brain imaging. After the surgical procedure, the patient was admitted to the intensive care unit to monitor consciousness and the presence of seizures or other neurological deficits. On the third day all the patients were discharged. The patient's symptom and outcome were evaluated until one year after surgery. This case series has been reported following the SCARE criteria and guidelines [6].

\* Medical Faculty of Universitas Kristen Indonesia, Jalan Mayjen Sutoyo, Cawang, 13630, Jakarta Timur, Indonesia.

E-mail address: [robertsinurat@yahoo.com](mailto:robertsinurat@yahoo.com).

<https://doi.org/10.1016/j.ijscr.2022.107101>

Received 1 March 2022; Received in revised form 14 April 2022; Accepted 15 April 2022

Available online 20 April 2022

2210-2612/© 2022 Published by Elsevier Ltd on behalf of IJS Publishing Group Ltd. This is an open access article under the CC BY-NC-ND license (<http://creativecommons.org/licenses/by-nc-nd/4.0/>).

## 2. Cases presentation

First case, a 28 years old female was admitted to the emergency room because of unconsciousness. She was working in her office when she felt a severe headache. Thirty minutes later her headache becomes worse and the patient dropped into unconsciousness. After arrived in the emergency ward, she was managed by oxygen administration and ringer's lactate infusion. The patient regained consciousness immediately but she still had a severe headache. Tramadol intra vein 100 mg administrations can relieve the symptoms from VAS score 10 into 4, and the patient can talk fluently. She and her mother mentioned that these symptoms were often happened to her and about three to four times a year in the last two years.

The vital sign was normal, blood pressure 117/71 mmHg, pulse rate 84×/min, respiration rate 18×/min, and no fever. Cranial nerve was normal except for sign of circumferential edema of both optic discs. The brain Ct-scan was performed but there was no subarachnoid hemorrhagic or any lesion except hypo-dense lesion at the left sub-temporal region (Fig. 1a). Magnetic resonance images showed the lesion hypointense on T1-weight and hyper-intense on T2-weight images. Also left M1 middle cerebral artery lay down inside the cyst (Fig. 1b). Blood examination including electrolyte and minerals was all normal.

The second case was a man 18 years old had seizures for the past two years and attacks every three months. He took phenytoin 300 mg a day from his neurologist, but in the last one month seizures repeated up to five times even though the dose was increased into 600 mg. Seizures were generalized, last about three minutes, and after the seizure the patient feel weak and had a headache. Cranial nerve examination was normal. The brain MRI results showed a hypointense lesion of T1-weight and hyperintense at T2-weight in the right temporal region measuring approximately 5 × 4 cm and compressing the temporal bone to form a convex shape (Fig. 2a & b).

The third case, a man 23 years old had complaints of seizures since 6 months before being consulted for neurosurgery. Seizures started from the right hands and eventually the whole body. It usually lasts 3–5 min and the patient remains conscious. The patient received the drug

phenytoin 3x100mg daily from a neurologist. During two months of taking phenytoin he never had seizures but in the last four month the seizures reappeared even though the dose was increased to 3 × 200 mg daily and combine with 1 g valproic acid. The brain MRI showed hyperintense lesion in the right temporal region on T2-weight image (Fig. 3).

### 2.1. Electroencephalography (EEG)

Interictal EEG examination was performed in second and third patients, while video EEG was not performed. The results of the EEG of the second and third patients showed there was no abnormal wave.

### 2.2. One year follow up

One year of following up after surgery, all of the patients is doing well. The first patient does not have any severe headache anymore and totally analgesic drugs free. The last two cases have never had a seizure after surgery and the dose of phenytoin is being reduced, currently it still 1 × 50 mg a day. All patients can return to work in better health condition.

## 3. Discussion

The author reported three cases of middle fossa arachnoid cysts in adult patients with clinical symptoms of severe headache or seizures, and microsurgery fenestration procedures eliminated the symptoms totally.

Headache, seizures or other symptoms occur in the arachnoid cyst was hypothesized because of increasing of intracranial pressure or dysfunction of local cerebral tissue [7,8]. It relates to the size and location of the cysts. One slit-valve mechanism was hypothesized as the cause of increasing arachnoid cyst's size [8,9]. In the first case, the patient fainted after experiencing intense headaches. It happened several times before surgery. This was related to the increasing of intracranial pressure, compression of the left middle cerebral artery which lay down

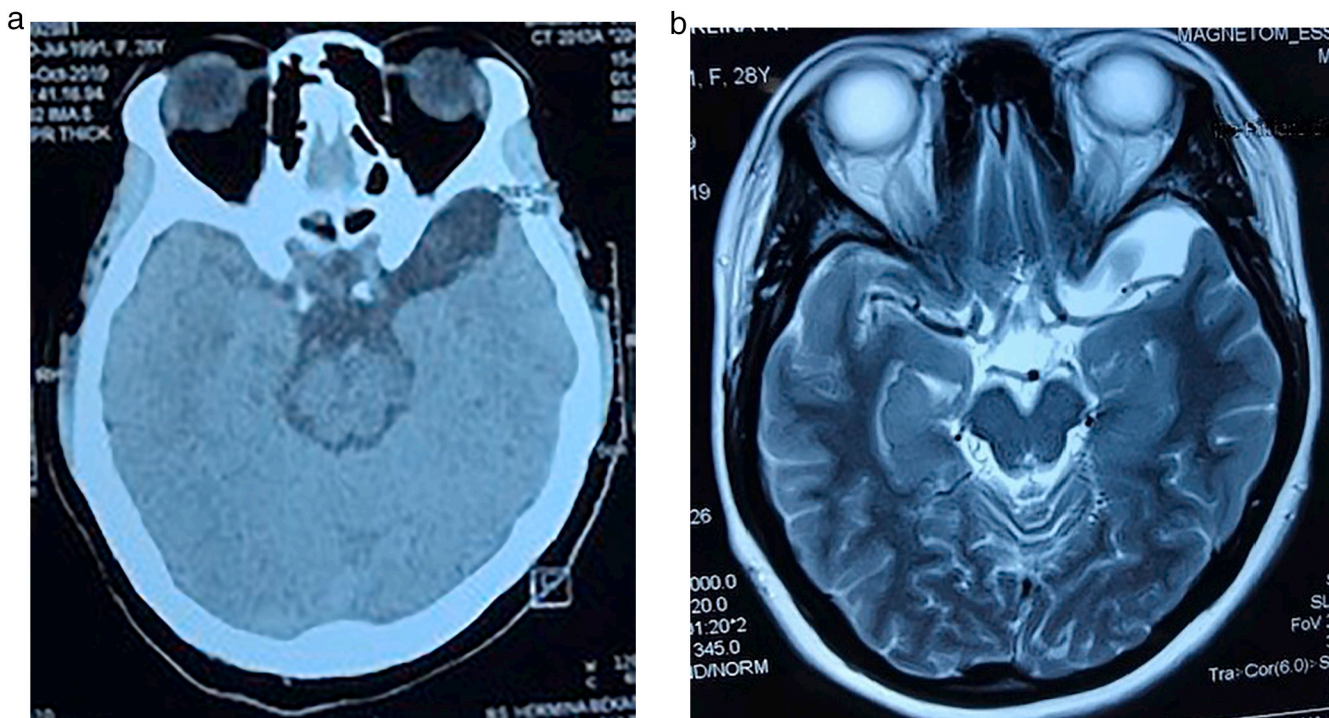


Fig. 1. a. Brain Ct-scan  
b. Brain MRI T2-weight.



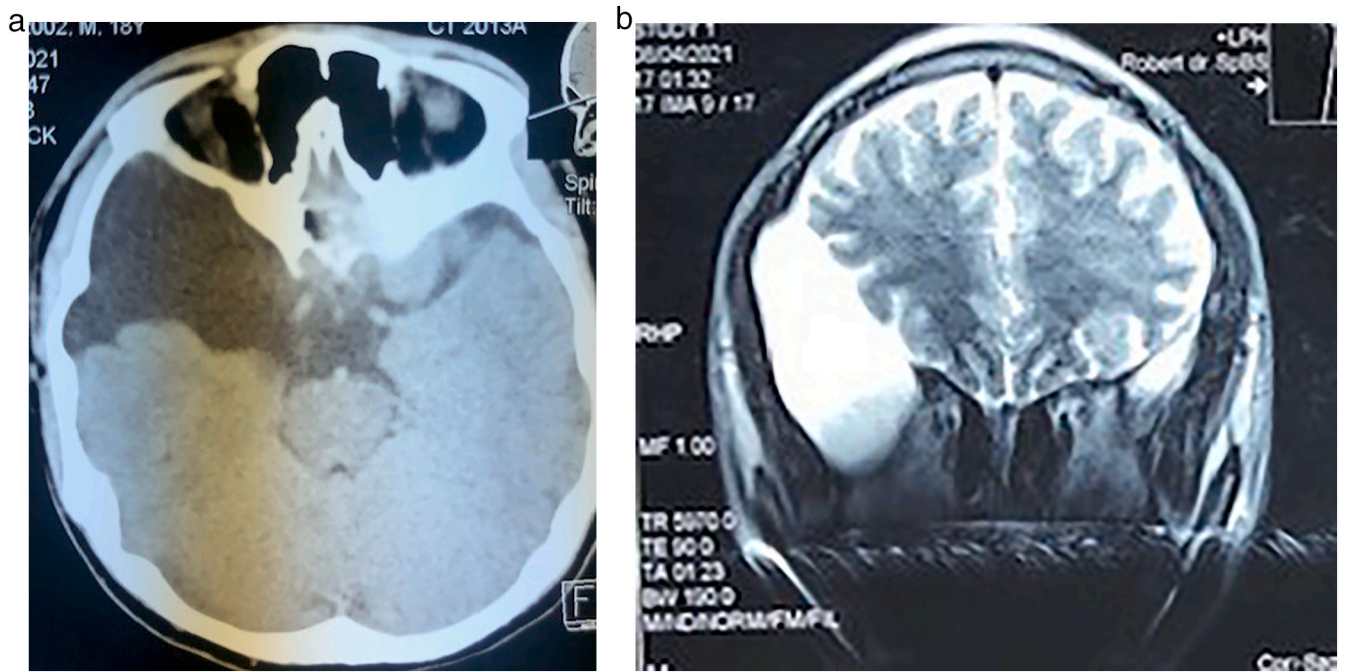


Fig. 2. a. Brain MRI T1-weight, axial view  
b. Brain MRI T2-weight, coronal view.

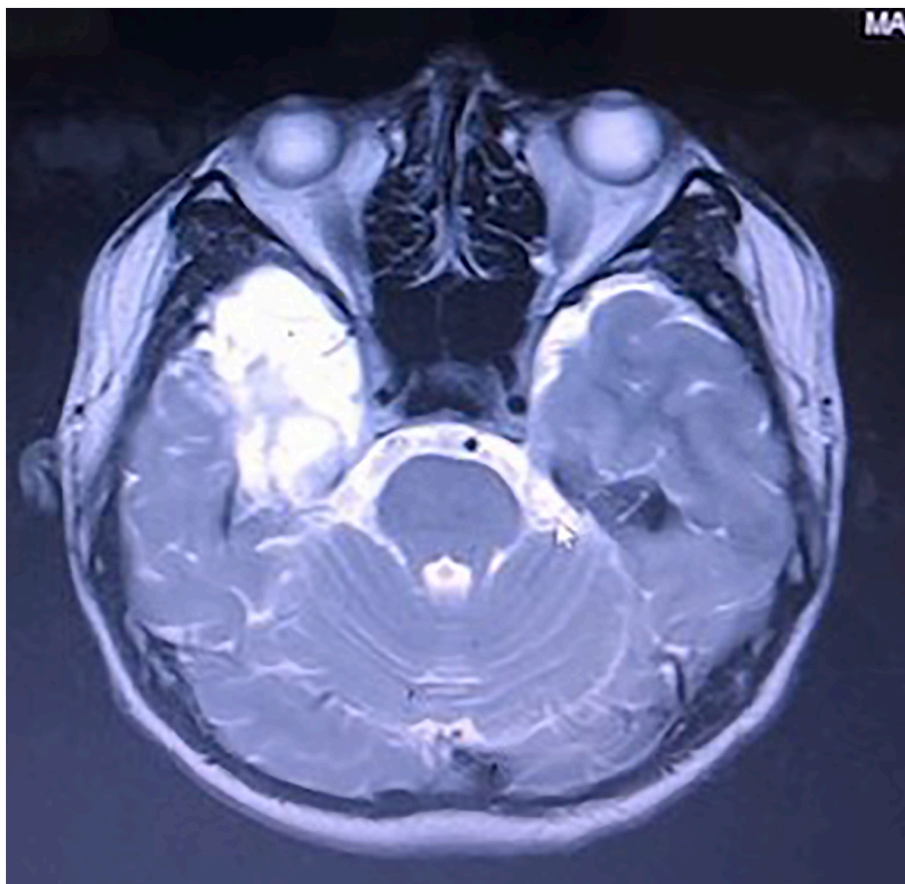


Fig. 3. Brain MRI T2-weight, axial view.

inside the arachnoid cyst and also the pain itself. Symptoms relieved after decompressing the pulsating arachnoid cyst by fenestration procedures and the pulsating were disappeared.

Clinical symptoms of seizure and localizing of abnormality of EEG features on interictal and video-EEG recording are the best indication for surgery of arachnoid cyst [10]. Unfortunately we do not have the facilities for this procedure and the surgery of the last two cases was performed based on the clinical symptoms, brain MRI, and drug resistance. In the second case, the temporal bone was thin and convex in shape. It supports the theory of the presence of high pressure within the cyst compares to its surroundings. Although in the third case there was no sign of an increase in the cyst pressure as in the second case, the relief of the patient's seizures despite the very low dose of phenytoin may suggest that the cyst related to the seizures.

Surgical procedures of the middle fossa arachnoid cyst by microsurgical fenestration and endoscopic methods are equally good. However, endoscopic fenestration was highly recommended because of less invasive and more safety [5,11,12]. The outcome of surgery on patients with symptomatic arachnoid cyst was good, especially the relieving of headache. The improvement was about 85.71 until 86.27% of all patients [13,14]. Although surgery on arachnoid cysts can reduce or eliminate the clinical symptoms, surgical complications can occur. Complications in the endoscopic fenestration procedure include cerebrospinal fluid leakage, subdural haematoma or hygroma. Whereas in microsurgical fenestration can occur meningitis, hydrocephalus, and subdural haematoma or hygroma [14].

#### 4. Conclusion

The result of microscopic fenestration craniotomy in patients with headaches and seizures due to middle fossa arachnoid cysts is good and recommended for controlling the seizures in selected cases.

#### Funding

The author received no financial support for this work.

#### Ethical approval

This study was carried out under the principles of the Declaration Helsinki. All of the patient's identity was not exposed in the text and images.

#### Consent

Written informed consent was obtained from the patients for publication of these cases and accompanying images. A copy of the written consent is available for the review by the editor-in-chief of this journal on request.

#### Research registration

Not applicable.

#### Guarantor

Dr.dr. Robert Sirait, SpAn: the Dean of Medical Faculty Universitas Kristen Indonesia as supervisor of lecturer's research and publications.

#### Provenance and peer review

Not commissioned, externally peer-reviewed.

#### CRediT authorship contribution statement

Robert Sinurat: design, data collection, wrote and revised the manuscript.

#### Declaration of competing interest

The author declared no potential conflicts of interest with respect to the research, authorship and publication of this article.

#### References

- [1] F. Mustansir, S. Bashir, A. Darbar, Management of arachnoid cyst: a comprehensive review, *Cureus* 10 (4) (2018), e2458, <https://doi.org/10.7759/cureus.2458>.
- [2] W. Al-Holow, S. Terman, C. Kilburg, H.J.L. Garton, K.M. Muraszko, Prevalence and natural history of arachnoid cysts in adults, *J. Neurosurg.* 118 (2) (2013) 222–231, <https://doi.org/10.3171/2012.10.JNS12548>.
- [3] G. Wojcik, Intracranial arachnoid cyst in the clinical and radiological aspect, *Wiad. Lek.* 69 (3pt2) (2016) 555–559.
- [4] R. Jafrani, J.S. Raskin, A. Kaufman, S. Lam, Intracranial arachnoid cysts: pediatric neurosurgery update, *Surg. Neurol. Int.* 10 (2019) 15, [https://doi.org/10.4103/sni.sni\\_320\\_18](https://doi.org/10.4103/sni.sni_320_18).
- [5] Y. Chen, H.J. Fang, J.F. Li, S.Y. Yu, C.Z. Li, Z.B. Wu, Treatment of middle cranial fossa arachnoid cysts: a systematic review and meta-analysis, *World Neurosurg.* 92 (2016) 480–490, <https://doi.org/10.1016/j.wneu.2016.06.046>.
- [6] R.A. Agha, T. Franchi, C. Sohrabi, G. Mathew, A. Kerwan, SCARE Group, The SCARE 2020 guideline: updating consensus surgical case report (SCARE) guidelines, *Int. J. Surg.* 84 (2020) 226–230, <https://doi.org/10.1016/j.ijsu.2020.10.034>.
- [7] J. Cherian, A. Viswanathan, R.W. Evans, Headache and arachnoid cysts, *Headache* 54 (7) (2014) 1224–1228, <https://doi.org/10.1111/head.12415>.
- [8] D. Kuruvilla, S. Haldal, J. Gaitanis, P. Klinge, Mechanisms of arachnoid cyst formation identified by positional headache, *Neurology* 80 (7supp) (2013). P01.090.
- [9] S.H. Halani, M.G. Safain, C.B. Heilman, Arachnoid cyst slit valves: the mechanism for arachnoid cyst enlargement, *J. Neurosurg. Pediatr.* 12 (2013) 62–66, <https://doi.org/10.3171/2013.4.PEDS12609>.
- [10] J.M.K. Murthy, Intracranial arachnoid cyst: epileptic seizures, *Neurol. India* 61 (4) (2013) 343–344, <https://doi.org/10.4103/0028-3886.117580>.
- [11] M. Pitsika, S. Sgouros, Volume change of cranial arachnoid cysts after successful endoscopic fenestration in symptomatic children, *Childs Nerv. Syst.* 35 (2019) 2313–2318, <https://doi.org/10.1007/s00381-019-04315-9>.
- [12] E.J. Lee, Y.S. Ra, Clinical and neuroimaging outcomes of surgically treated intracranial cysts in 110 children, *J. Korean Neurosurg. Soc.* 52 (4) (2012) 325–333, <https://doi.org/10.3340/jkns.2012.52.4.325>.
- [13] M.M. Rahman, U.K.S. Zaman, Surgical outcome of endoscopic cysto-cisternostomy for arachnoid cyst, *Ann. Int. Med. Den. Res.* 5 (1) (2019), <https://doi.org/10.21276/aimdr.2019.5.1.MC1.MC01-MC03>.
- [14] C. Wang, C. Liu, Y. Xiong, G. Han, H. Yang, H. Yin, et al., Surgical treatment of arachnoid cysts in adult patients, *Neurol. India* 61 (2013) 60–64, <https://doi.org/10.4103/0028-3886.108013>.