

VOLUME : 28
NUMBER : 02
APRIL - JUNE, 2018

ISSN 1560 - 9014 - PRINT
ISSN 2413 - 7650 - ONLINE



JPAD

www.jpada.org.pk

Journal of Pakistan Association of Dermatologists

A Publication of:
PAKISTAN ASSOCIATION OF DERMATOLOGISTS

Journal of Pakistan Association of Dermatologists

Volume 28, Number 2 April-June, 2018

Editor

Ijaz Hussain

Associate Editors

Farhana Muzaffar

Faria Asad

Zahida Rani

Shehla Shaukat

Publication Manager

Abdul Hameed

Editorial Board

	Pakistan	Overseas
Amer Ejaz	Nasser Rashid Dar	Aisha Sethi (USA)
Arfan ul Bari	Shahbaz Aman	Ayyaz Shah (USA)
Asher Ahmad Mashhood	Shahbaz Janjua	Ian McColl (Australia)
Azim Jahangir Khan	Shahid Jawaid Akhtar	Imtiaz Ahmad (UK)
Doulat Rai Bajaj	Syed Dilawar Abbas Rizvi	Jyakar Thomas (India)
Ghulam Mujtaba	Syed Shamsuddin	Khalid Al Aboud (KSA)
Ijaz Ahmad	Rehanuddin	
Jamil Ahmad Shaheen	Tahir Jamil Ahmad	MR Namazi (Iran)
Mahmood Noor	Tariq Rashid	
Mansoor Dilnawaz		
Muhammad Khalid	Yasmeena Khan	
Naeem Raza	Zafar Iqbal Sheikh	
Naseema Kapadia		

JPAD, the official journal of Pakistan Association of Dermatologists is published quarterly, four issues per volume and one volume per year (ISSN 1560-9014, print; ISSN 2413-7650, online). The journal is recognized by Pakistan Medical and Dental Council and is indexed in College of Physicians and Surgeons Pakistan MEDLIP; Ulrich's International Periodical Directory, USA; ExtraMED, London; EMBASE/Excerpta Medica, PakMediNet, The Netherlands; and Index Medicus, WHO Alexandria, Egypt.

Subscription

A complimentary copy of the journal is provided to all PAD members. Subscription rates per volume are Rs. 4000.00 for Pakistan, £80.00 for UK and \$120.00 for US and the rest of world.

Copyright

© 2018 Any material published in JPAD is copyright of Pakistan Association of Dermatologists.

Journal of Pakistan Association of Dermatologists

Volume 28, Number 2 April-June, 2018

Contents

Editorial

- Choice of second fellowship in dermatology 121
Asher Ahmed Mashhood, Zafar Iqbal Sheikh, Syeda Komal Bukhari

Original Articles

- Distribution of CD4+RORg-T Th17 and CD25+ FOXP3+ Treg in leprosy patients with reversal reaction 123
R Yuniati, W Riawan, D Widasmara, IGN Darmaputra, S Arifin
- Relationship of amino acid concentrations in blood with occurrence of dermatophytosis 129
Farzan Hayeri Khiavi, Aliasghar Gharachorlu
- Silicon level in skin tissues of normal female individuals 134
Ago Harlim, Siti Aisah, Riwandi Sihombing
- Effect of intense pulsed light on topical steroid-dependent facial dermatitis 139
Parineeta Maria, Nitin Mishra, Madhur Rastogi, Pratik Gahalaut
- Effect of 30% salicylic acid peels in mild to moderate acne vulgaris: a hospital-based nonrandomised clinical study 146
Bava Aneesh, Joy Bifi, Anoop Thyvalappil, Sridharan Rajiv, Sreenivasan Ajayakumar, Mathew Pretty
- Trichoscopic features in diagnosis of alopecia areata and its relation to severity of alopecia tool (SALT) score 152
Sarah Elizabeth Dias, Vinitha Varghese Panicker, Jacob Thomas, Soumya Jagadeesan, Gopikrishnan Anjaneyan, Lekshmi S
- Use of Skindex-29[®] to assess quality of life in patients with port-wine stain 157
Talat Masood Akbar, Haroon Nabi, Mahmood A. Saqib, Hamdah Aftab, Hira Khalil, Sobia Khakwani, Izza Raza Sahi
- Bullous pemphigoid treated with dexamethasone-cyclophosphamide pulse therapy 163
Ramji Gupta
- Clinico-epidemiological study of alopecia areata 168
Arun Achar, Sanjay K Rathi, Leishiwon Kumrah, Rabindranath Biswas, Samiran Bisai

Quality of life in patients with alopecia areata attending dermatology department in a tertiary care centre - A cross-sectional study <i>Fasalul Abideen, Anoop Thy Valappil, Pretty Mathew, Ajayakumar Sreenivasan, Rajiv Sridharan</i>	175
The impact of hirsutism on the mental status of Indian women <i>KC Kiran, A Gupta, M Gupta</i>	181
Quality of life assessment in patients of psoriasis <i>Saima Rahman, Shahbaz Aman, Nisaruddin, Muhammad Nadeem, Atif Hasnain Kazmi</i>	186
Efficacy and safety of thalidomide in treatment of prurigo nodularis <i>Uzma Ahsan, Sumara Rashid, Uzair Wazir</i>	193
Frequency and association of dermatological manifestations of type 2 diabetes mellitus with body mass index and HbA1c levels <i>Uzma Sarwar, Habib Ur Rehman, Sumara Rashid, Muhammad Azam Bokhari</i>	199
Spectrum of mucocutaneous manifestations of diabetes mellitus in Jharkhand <i>Firdous Jahan, Pooja Choubey, Ankur Ghosh, Shyam Sundar Chaudhary, Prabhat Kumar</i>	207
Clinical spectrum of pediatric dermatoses at a tertiary care unit <i>Rabia Mukhtar, Nadia Ali Azfar, Lamees Mahmood Malik, Muhammad Jahangir, Tariq Rashid</i>	214
Physiological skin changes during pregnancy <i>Shanza Ikram, Aisha Malik, Majid Suhail</i>	219
A comparative study of the resurfacing effect of microdermabrasion versus glycolic acid peel in the management of acne scar <i>Pallavi Rathi Vanthitha, Seethalakshmi Ganga Vellaisamy, Kannan Gopalan, Govindarajan Nanjappachetty</i>	224
Lactic acid peeling in the treatment of epidermal melasma <i>Saadiya Siddiqui, Tariq Rashid</i>	233
Comparison of efficacy and safety of topical betamethasone valerate 0.1% with narrowband-UVB in atopic dermatitis <i>Rajani Agrawal, Bushra Bashir, Sadia Qayyum, Sara Inayat, Khawar Khurshid, Sabrina Suhail Pal, Faria Altaf</i>	239
Surgical Commentary	
Medical form for a patient with malignant melanoma of the skin, made in accordance to the most recent guidelines for diagnosing, treating and monitoring the disease <i>Strahil Strashilov, Veselin Kirov, Angel Yordanov, Vasil Nanev, Miroslava Mihailova, Ilko Iliev</i>	245

Review Article

- Skin biopsy- some key concepts and guidelines 250
Aisha Ghias

Case Reports

- Ascher's syndrome: A rare entity with subclinical hypothyroidism 256
Niraj Parajuli
- An asymptomatic sessile nodule on the scalp: nodular hidradenoma 258
Vishalakshi S. Pandit, Sanjay Desai
- Female pseudohermaphroditism: Congenital adrenal hyperplasia presenting with diffuse hyperpigmentation 262
Wajieha Saeed, Ghazala Butt, Khawar Khurshid
- Giant arteriovenous malformation of scalp - A rare case report 266
PV Bhagwat, V Kuntoji, C Kudligi, GC Patil, PV Nayak

Short Communication

- A case of annular alopecia areata of the scalp 270
Mohammad Adil, Syed Suhail Amin, Mohd. Mohtashim, Roopal Bansal, Annu Priya

Information for authors

272

Over the last 3 years the faculty of dermatology at College of Physicians and Surgeons has worked on the development of FCTS program in pediatric dermatology, dermatopathology and dermatology. Our responsibility now is to ensure that the program could reach to completion the in-quest to meet the college criteria to start a specialty program. The maximum effort and time have been devoted to Pediatric Dermatology and program progress has been made in this discipline but there is a constant concern by the FCTS program dermatology that the responsibility is not in popular demand and they want FCTS Dermatology to be introduced before any other specialty program.

Several sub-specialty programs are being offered worldwide for mostly in India and USA. One-year fellowship in Pediatric Dermatology is being offered at several universities. Similarly following programs and certificates in academic dermatology, Dermatology and Dermatopathology are also available internationally. Except dermatopathology, other subspecialties are still in the developmental phase regarding their standard curricula, training requirements and certification. www.fcts.org is the main website for information. College of Physicians and Surgeons Pakistan has always taken a lead in introduction of several new subspecialties. www.fcts.org is the main website for certification.

Address for correspondence:
 Dr. Amir Ahmad Mashood
 Dermatology Department
 Combined Military Hospital, Faisalabad
 Email: amir.mashood@ghoc.com

Silicon level in skin tissues of normal female individuals

Ago Harlim, Siti Aisah, Riwandi Sihombing

Department of Dermatology and Venereology, Christian University of Indonesia, Jakarta, Indonesia

Abstract

Objective To evaluate silicon level in normal skin tissue.

Methods The silicon levels in skin samples were measured using an atomic absorbance spectrophotometer in 37 healthy normal females who had never received silicone injection and compared with those who had developed granuloma after silicone injection..

Results Low silicon level ($44.07 \pm 75.86 \mu\text{g/g}$) was found in skin tissues of normal individuals as compared to those who developed post-silicone granuloma ($1709.21 \pm 1851.72 \mu\text{g/g}$).

Conclusion Silicon may be found in normal skin tissue due to daily use of cosmetic products; however the level is significantly low.

Key words

Silicon, skin, topical, accumulation.

Introduction

Silicon is a chemical element, which has a symbol of Si and an atomic weight value of 28. It is not a metal element and it actually has semimetallic characteristics, which means that silicon does not stand as a single atom, but rather as a chemical compound of silicon dioxide or a complex compound or silicon silicate.¹ In addition, silicone is a cross-linked polymer with methyl siloxane as the basic element. Polydimethylsiloxane (PDMS) is the most common silicone, which has been used in many kind of preparations such as liquid, gel and solid.^{1,2} Polymerization and the length of siloxane chain may affect its viscosity, which is measured in units of centistokes (cS). Silicone has some degree of resistance to react with

oxidizing agents, such as nitric acid, sulfuric acid, chlorine and other fluids, which are more hydrophobic than fluids with similar viscosity to silicone.^{2,3}

In daily life, many people have been exposed to silicones in the form of simethicone (antifoams used in antacids), silicone oil as a lubricant for syringes and cerebrospinal shunt tubes. Silicones are also found in cosmetic products such as hair conditioner and shampoo to give hair a silky and dazzling shine. Moreover, metalloids silicone crystals have been used widely for various needs such as transistors, electronic microchips, computers and household utilities.⁴

The use of silicone injection for reconstruction of face and other body parts was started in 1963 with a total of 200 patients in Las Vegas. Severe inflammatory effect was noted and therefore, the application was stopped. At that time, the type of injected-silicon was industrial grade with low purity and high viscosity; therefore, serious side

Address for correspondence

Dr. Ago Harlim
Department of Dermatology and Venereology,
Christian University of Indonesia,
Jakarta, Indonesia.
Email: agoharlim@yahoo.com

effects such as severe inflammation were certainly found. Later, the Dow Corning Corporation produced sterile and injectable silicone with high purity and low viscosity (350cS) characteristics.² Afterwards, in 1977, Wilke obtained data of 92 individuals who had received the injectable-grade silicone injections and noticed that there were inflammatory reactions with granuloma formation in 8 individuals, which developed within a year after the injection. Ten years later, granuloma formation was also found in the other 13 individuals. On the contrary, Arohnsohn injected subcutaneous silicone in 1984 using pure and sterilized-silicon to 4,863 individuals aged over 22 years. As a result, no side effect was found.²

Since evidence-based data have been inconsistent, particularly regarding the indication and adverse effects of silicone use, FDA has decided to ban the use of silicone as filler material. However, there are still a lot of ways of silicon entering our body parts other than injection such as through oral pathway into digestive system by intake of some foods containing high levels of silicon or topical pathway by the use of face cream. Our study evaluated the silicon levels found in normal skin tissue and discussed the possible mechanisms of how the molecule can enter and migrate along our body systems. There was no prior study has reported the levels of silicon in normal skin tissues.

Methods

Subjects

37 healthy normal women participated in our study. We had requested their approval to examine their skin sample obtained from face-lift procedure. The subjects had never received silicone injection and their silicon (Si) levels were compared to other subjects who had

received liquid silicone injection with a development of granuloma formation. The skin sample of subjects with granuloma were isolated from the granuloma tissue located in submental area. The skin samples were isolated from of facial area of both subject groups.

Measuring silicon (Si) levels using Atomic Absorbance Spectrophotometer

The skin samples were analyzed and the silicon levels were measured using an atomic absorbance spectrophotometer (AAS) at an analytical chemical laboratory in Faculty of Mathematic and Natural Sciences, University of Indonesia. The levels were measured as microgram of silicon per gram of skin tissue.

Results

Figure 1 shows data about the levels of silicon in both subject groups. The mean silicon level in the skin samples of normal subjects was $44.07 \pm 75.86 \mu\text{g/g}$ and a 38-fold higher level of silicon was found in the skin sample of subjects with granuloma ($1709.21 \pm 1851.72 \mu\text{g/g}$). There was a significantly higher level of silicon in subjects with granuloma as compared to the normal subjects. However, there was still a low level of silicon detected in the normal subjects.

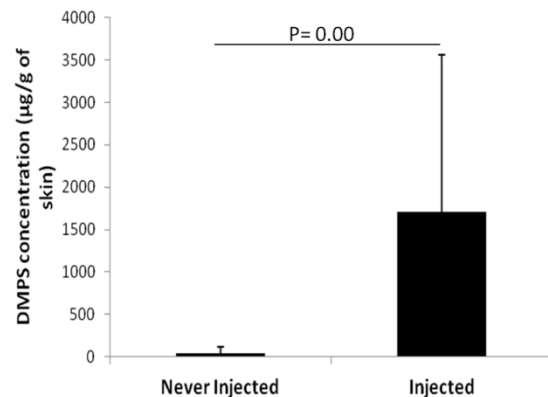


Figure 1 The level of silicon (Si) in normal subjects who had never received silicone injection (never injected) and in subjects with granuloma who had received silicone injection (injected)

In the normal subject group, there were 15 subjects who had silicone in their skin samples; while in the other 22 subjects, no silicon level was detected.

Discussion

Silicon has been claimed as a stable and inert element.^{5,6} With such unique properties, manufacturing companies have been producing injectable-grade silicone for medical use. For example, transconjunctival injection of silicone oil has been used to treat complicated retinal detachment and heavy silicone oil tamponade has been promising good prognosis for retinal reattachment, as well as, improving visual acuity and providing successful results on other anatomical parameters. Nevertheless, some complications such as mild inflammation, increased ocular pressure, cataract and heavy silicone oil emulsification may arise.⁷⁻⁹

Silicone oil injection has also been applied to reduce the risk of developing diabetic foot ulcer. Some other studies have reported that silicone oil has pressure-reducing properties and it may have a role in increasing plantar tissue thickness.^{10,13} In spite of the advantages, some complications may still arise. Another study report showed that silicone injection in lower extremity could develop palpable nodule around injection area, as well as, electrical sensation, muscle fatigue, joint pain and electrical neuropathy.¹⁴ In addition to those local complications, systemic complications have also been reported including lymphadenopathy, renal disease and hepatic disease. It indicates that injected silicone can migrate from injection site to other body parts. In experimental mice model, the injected silicone could be engulfed by macrophages in skin tissue, recirculated via lymphatic vessels and accumulated in adrenal glands, lymph nodes, liver, spleen and kidney.¹⁵ In diabetic ulcer patients, migration of silicone

that has been implanted into their foot may be correlated with biomechanic activity of foot itself.

Granuloma formation due to silicone injection is dose-dependent. **Figure 1** shows that only a large amount of silicon caused granuloma formation as there was a low level of silicon in the skin tissue of normal subjects, but no granuloma formation was documented.

In addition to its medical application, silicone has also been used in food, cosmetics and pharmaceutical industries. Previous data demonstrated that the silicon (Si) levels in digestive drugs such as antacids, mineral water and soft drink was 44.1, 25.6, and 2.91 $\mu\text{g/g}$ silicone, respectively. Therefore, we can say that there are a lot of routes of silicone entering into our body.

The average daily dietary intake of silicon is 20-50 mg for European and North American populations. Daily intake of silicon is higher in China and India (140-200 mg/day) where grains, fruits and vegetables form a larger part of the diet.¹

Recently, a research institution of healthy aging and nutrition in UK has reported a strong correlation between silicon diet and the health of bone and connective tissue. It is assumed that the correlation is associated with collagen synthesis and/or stabilization, as well as, mineralization of the matrix, in which silicone intake has some effects on bone density.¹⁶

An animal experimental study, showed that there was no evidence about silicone accumulation in oral silicone intake. Silicone can be eliminated by numerous routes including feces (93-97%), urine (0.001-0.22%) and exhaled air (0.01-0.02%).³ It indicates that silicone is a stable element and can have a certain degree of

resistance against enzyme digestion, as well as, acidic gastric condition. Therefore, it is unlikely for silicone to accumulate in gastrointestinal system.

Beauty products for face, hair and cosmetics may contain a higher level of silicone, which is more likely to be accumulated in skin tissue. When topical silicone products are applied to the skin, silicone elastomeric particles can absorb various liquids including emollient and sebum. Therefore, it can be used for skin care as delivery vehicles for some active ingredients to the skin or to control sebum deposition in the skin.¹⁷

The capability of silicone elastomeric particles to expand in certain solvents has prompted their utility as therapeutic delivery agent for skin care. This unique capability and in addition to the surface area of silicone elastomeric particles can absorb various kind of oils and make the skin stay dry when it is touched. Therefore, the silicone elastomeric particles can be used as an agent to carry certain oil or ingredients or as emollient for the skin and act as mineral oil, glycerides, fat esters and sunscreen.¹⁸

Silicone elastomeric particles, which are covered by nanoparticles such as Al₂O₃ or TiO₂, have shown soft-focus effect. In a simple description, it can be said that the soft-focus effect becomes obvious when there is minimum reflection (<20% of total illumination), maximum total transmission (>75% of total illumination); while the disperse illumination reflection is maximum (80%) and the disperse illumination has maximum transmission (>50%).¹⁷

When these criteria are fulfilled, the total transmission illumination reflects natural skin tone similar to the back light effect and provides natural light; while the disperse transmission will even create better skin glow and hides

imperfection.¹⁸ Silicone elastomeric particles, which have been enhanced with SiO₂ particles have been proven to minimize wrinkles.¹⁷

Silicon accumulation in the skin is probably caused by topical use of applying cosmetic products, which contain silicone. The penetration of chemicals that are contained in cosmetic products is influenced by molecular size, lipophilicity, pH, penetrant concentration, chemical enhancers, skin hydration, skin enzymes, and temperature. Manipulating these parameters could drive the dermatokinetic of chemical compounds that are contained in cosmetic products.¹⁸

In skin cream, silicon could form water-repellent layer to protect skin. Nonetheless, silicon has a large molecular size and it is impossible for silicon to penetrate skin layer without any enhancer. Another ingredient contained in the skin cream can enhance silicon penetration into deeper layer of the skin. Low level of silicon found in the skin tissue of normal subjects in our study might be caused by daily use of skin cream. Thus, it is unlikely that normal subjects have no silicon level in their skin. Therefore, greater consideration must be taken in new technology on absorption mechanism when applying topical cream on the skin including nanotechnology, which can penetrate into the skin and in the long-term it may develop into granuloma.

Conclusion

The use of silicone as filler material has been banned by FDA. Nevertheless, there are still some risks of using topical silicone, particularly cosmetic products that contain silicone. Bioavailability of silicone in skin tissues and long-term complications of silicone use must be evaluated for safety reasons. Moreover, further

studies should be done on how silicon can penetrate into skin tissue.

References

1. Price CT, Koval KJ, Langford JR. Silicon: A review of its potential role in the prevention and treatment of postmenopausal osteoporosis. *Int J Endocrinol*. 2013; Article ID 316783:1-7.
2. Chasan PE. The history of injectable silicon fluids for soft-tissue augmentation. *Plast Reconstr Surg*. 2007;**120**:2034-40.
3. Eighteenth Report of the Joint FAO/WHO Expert Committee on Food Additives, Wld Hlth Org. techn. Rep. Ser., 1974, No. 557. FAO Nutrition Meetings Report Series, 1974, No. 54. <http://www.inchem.org/documents/jecfa/jecmono/v06je42.htm>
4. Teuber S, Yoshida S, Gershwin E. Immunopathologic effects of silicone breast implants. *West J Med*. 1995;**162**:418-25.
5. Narins RS, Beer K. Liquid injectable silicon: A review of its history, immunology, technical, consideration, complication, and potential. *Plast Reconstr Surg*. 2006;**118**:Suppl.77S.
6. Elson ML. Injectable silicon for soft tissue augmentation. *Cosmet Dermatol*. 2005;**18**: 773-4.
7. Siqueira RC, Gil AD, Jorge R. Retinal detachment surgery silicon oil injection in transconjunctival sutureless 23-gauge vitrectomy. *Arg Bras Oftalmol*. 2007;**70**(6):905-9.
8. Prazeres J, Magalhaes Jr O, Lucatto LFA, Navarro RM, Moraes NS *et al*. Heavy silicon oil as a long-term endotamponade agent for complicated retinal detachments. *BioMed Res Int*. 2014; <http://dx.doi.org/10.1155/2014/136031>
9. Duan A, She H, Qi Y. Complications after heavy silicon oil tamponade in complicated retinal detachment. *Retina*. 2011;**31**:547-52.
10. Van Schie CH, Whalley A, Armstrong DG, Vileikyte L, Boulton AJ. Efficacy of injected liquid silicon in the diabetic foot to reduce risk factors for ulceration: A randomized double-blind placebo-controlled trial. *Diabetes Care*. 2000;**23**:634-8.
11. Van Schie CH, Whalley A, Armstrong DG, Vileikyte L, Boulton AJ. The effect of silicon injections in the diabetic foot on peak plantar pressure and plantar tissue thickness: A 2-year follow-up. *Arch Phys Med Rehabil*. 2002;**83**:919-23.
12. Wallace WD, Balkin SW, Kaplan L, Nelson S. The histological host response to liquid silicon injections for prevention of pressure-related ulcers of the foot: A 38-year study. *J Am Podiatric Med Assoc*. 2004;**94**:550-7.
13. Gaber Y. Secondary lymphotoedema of the lower leg as an unusual side-effect of a liquid silicon injection in the hips and buttocks. *Dermatology*. 2004;**208**:342-4.
14. Merrill TJ, Mustafa ZC, Beverly M, Hernandez J. Silicon injection complications in the lower extremity: Migration, local reaction, and autoimmune response. http://www.podiatryinstitute.com/pdfs/Update_2010/2010_39.pdf
15. Ben-Hur N, Ballantyne DL Jr, Rees TD, Seidman I. Local and systemic effects of dimethylpolysiloxane fluid in mice. *Plast Reconstr Surg*. 1967;**39**:423-6.
16. Jugdaohsingh R. Silicon and bone health. *J Nutr Health Aging*. 2007;**11**:99-110.
17. Liles DT, Lin F. Silicon Elastomeric Particles in Skin Care Applications. Science & Technology Department. 2010. Vol 1053. Chapter 11. P. 207-19.
18. Nair A, Jacob S, Al-Dhublab B, Attimarad M, Harsha S. Basic considerations in the dermatokinetics of topical formulations. *Bras J Pharmaceut Sci*. 2013;**49**:423-34.

also developed by scimago:



SCIMAGO INSTITUTIONS RANKINGS

SJR

Scimago Journal & Country Rank

Enter Journal Title, ISSN or Publisher Name

Home

Journal Rankings

Country Rankings

Viz Tools

Help

About Us

Journal of Pakistan Association of Dermatologists

10

H Index

Country [Pakistan](#) - [SJR Ranking of Pakistan](#)

Subject Area and Category [Medicine](#)
[Dermatology](#)

Publisher [Pakistan Association of Dermatologists](#)


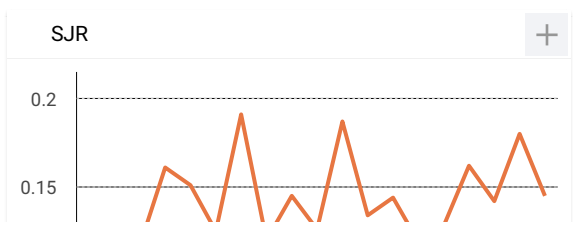
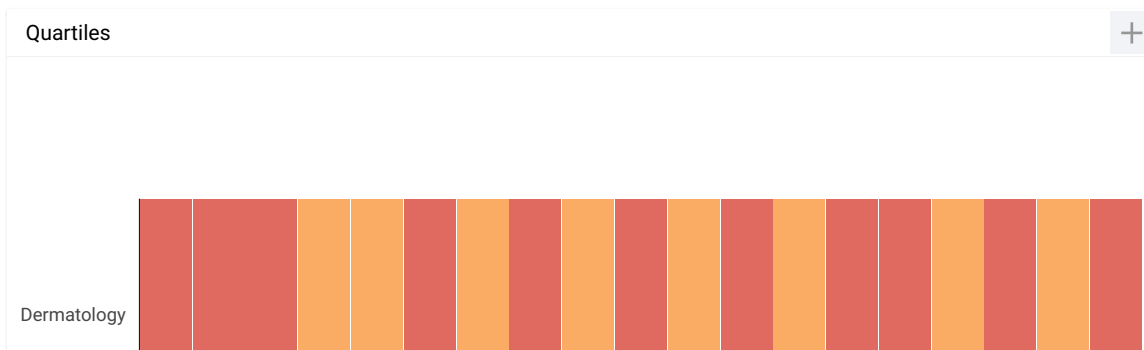
Publication type [Journals](#)

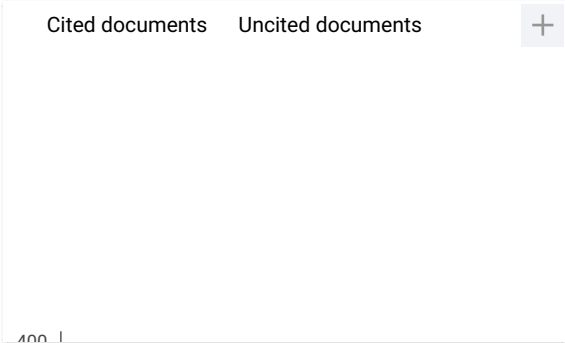
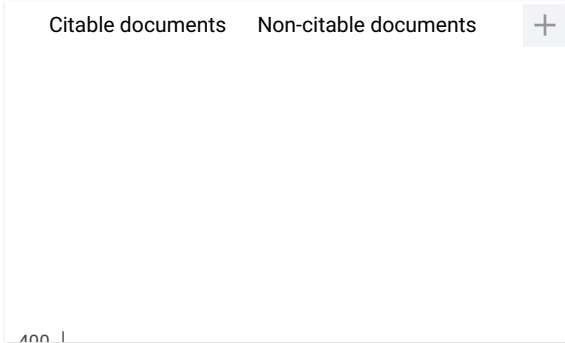
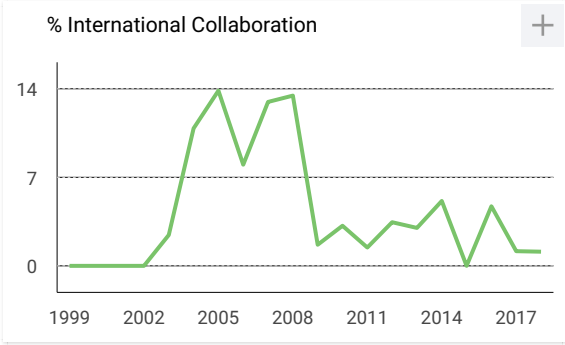
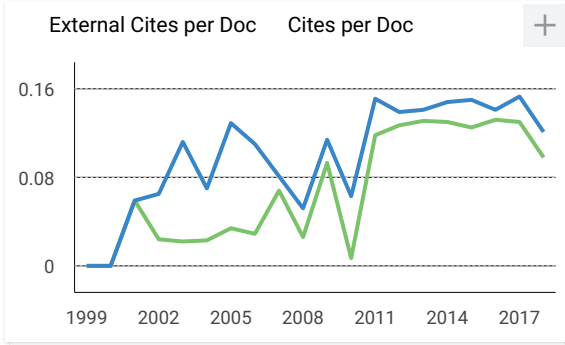
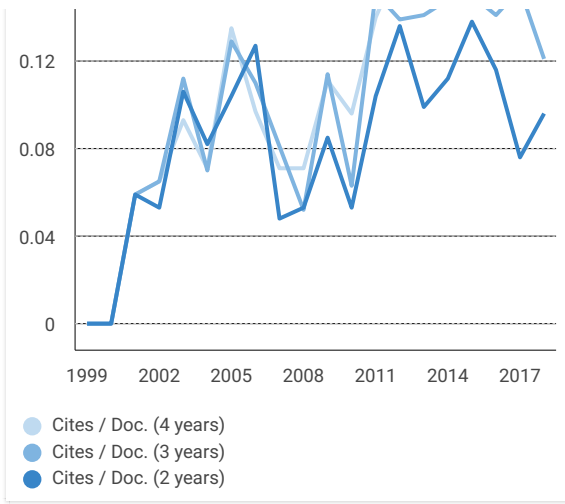
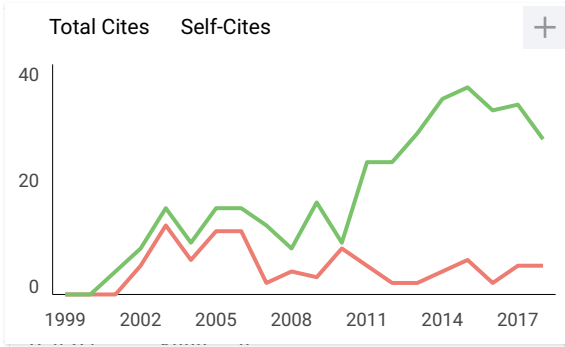
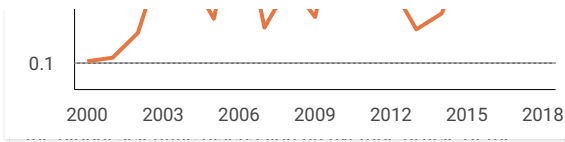
ISSN [15609014](#)

Coverage [1999-ongoing](#)

[Homepage](#)

[Join the conversation about this journal](#)





Journal of Pakistan Association of...

Q4 Dermatology

best quartile

SJR 2018

0.15

powered by scimagojr.com

← Show this widget in your own website

Just copy the code below and paste within your html code:

```
<a href="https://www.scimagojr.com/journalsearch.php?q=24878&tip=sid&clean=0"
```

Leave a comment

Name

Email

(will not be published)

I'm not a robot reCAPTCHA
Privacy - Terms

Submit

The users of Scimago Journal & Country Rank have the possibility to dialogue through comments linked to a specific journal. The purpose is to have a forum in which general doubts about the processes of publication in the journal, experiences and other issues derived from the publication of papers are resolved. For topics on particular articles, maintain the dialogue through the usual channels with your editor.

Developed by:



Powered by:



Follow us on @ScimagoJR

Scimago Lab, Copyright 2007-2020. Data Source: Scopus®

EST MODUS IN REBUS
Horatio (Satire 1.1.106)