

TurnitinTheComparisonoftheUse ofSpinalAnesthesiawith

by Robert Hotman Sirait

Submission date: 07-Jan-2021 02:21PM (UTC+0700)

Submission ID: 1484009401

File name: TheComparisonoftheUseofSpinalAnesthesiawith.pdf (826.19K)

Word count: 5315

Character count: 29520

The Comparison of the Use of Spinal Anesthesia with General Anesthesia in Appendectomy Patients at *Rumah Sakit Umum Universitas Kristen Indonesia* from January 2016 - August 2018

Robert Hotman Sirait

Department of Anesthesiology, Medical Faculty, *Universitas Kristen Indonesia*

Abstract:

Anaesthesia is an essential process before doing surgeries in order to eliminate the pain and ease the surgery process. Spinal anaesthesia and general anaesthesia are two kinds of anaesthesia used for appendectomy patients. Spinal anaesthesia is regional anaesthesia that prevents neurons' pain stimulation to subarachnoid space by using local anaesthesia. In contrast, general anaesthesia is the situation where pain elimination and the loss of consciousness happen temporarily, which are the results of the suppression of the central nervous system. This research is using retrospective study case, which the data is taken from the secondary data in the form of medical records from the spinal anaesthesia and general anaesthesia patients of The Christian University of Indonesia hospital in January 2016 – August 2018. The process of taking data is based on the inclusion criteria. In the inclusion criteria, the patients must be males or females in the age of 17 above and have done the elective surgeries. After the research has been done, it is found that the sum of the appendectomy patients using spinal anaesthesia is more than the ones who are using the general anaesthesia. Based on the sex of the patients, females are more than males in terms of using either spinal anaesthesia or general anaesthesia in the average age of 17-25.

Keywords: Spinal anaesthesia, General Anesthesia, Appendectomy Patients

1. INTRODUCTION

Appendicitis is a condition where there is an infection of the tassel of worms (Appendix Vermiformis). Furthermore, become a problem in some countries such as America and Europe. About 7% of the American population has appendicitis with an incidence of 1.1 per 1000 population per year. In mild cases, it resolves without treatment, but many cases require surgery with the removal of infected tufts [1]. Appendicitis can be found at all ages, only in children less than one-year-old is rarely reported because the appendix in infants is conical, comprehensive at the base and narrows towards the tip. This situation causes a low incidence of appendicitis at that age. In the form of physical signs and symptoms, appendicitis is a prototype disease that progresses through inflammation, obstruction and ischemia over a variable period [2; 3]. The incidence of appendicitis in the world in 2007 reached 7% of the total world population. The incidence of appendicitis in developed countries is more significant than in developing countries. Data from the Ministry of Health in 2008 showed that the incidence of appendicitis in Indonesia

was the highest among other abdominal emergency cases. One in 15 people have suffered from appendicitis in their life. Namely, the number of appendicitis sufferers in Indonesia reached 591,819 people, and the incidence of appendicitis increased in 2009 by 596,132 people [4; 5; 6].

According to WHO (World Health Organization), the incidence of appendicitis in Asia in 2004 was 4.8% of the total population. According to the Indonesian Ministry of Health in Indonesia in 2006, appendicitis was the fourth most common disease after dyspepsia, gastritis and duodenitis with 28,040 hospitalized patients. Besides, in 2008 the incidence of appendicitis in Indonesia was the highest among other abdominal emergency cases [7; 8; 9]. The initial symptom of acute appendicitis is pain or discomfort around the umbilicus. These symptoms generally last more than 1 or 2 days. Within a few hours, the pain shifts to the right lower quadrant accompanied by anorexia, nausea and vomiting. There may also be tenderness around McBurney's point. Then there is muscle spasm and lose tenderness. If the appendix ruptures, signs of perforation can include pain, tenderness and spasm [10; 11].

If the diagnosis of appendicitis is precise, the most appropriate course of action is appendix surgery (appendectomy). Surgery is an operative procedure by opening and exposing the body part to be treated in an invasive way [12; 13]. Based on the results of the Health Office Survey in Indonesia, acute appendicitis is one of the causes of acute abdomen and is an indication for emergency surgery. In several cities in Indonesia, namely the city of Gorontalo, data was obtained from the Sub Division of the Medical Record that the number of patients who underwent appendectomy surgery in 2014 out of around 1,606 general surgery patients, 576 of whom underwent appendectomy or about 35.87% in 2014. In 2015, out of 1,431 general surgery patients, 455 of them underwent appendectomy or around 31.79%. For this reason, the authors took the initiative to write and examine the comparison of the use of spinal anaesthesia with general anaesthesia in appendectomy patients at the *RS UKI Jakarta* from January 2017 - August 2019.

Based on the background of this study, the researchers' questions can be concluded, namely: 1) How many appendectomy patients used spinal anaesthesia at the *RS UKI Jakarta* from January 2017 -August 2019 ?; b) How many appendectomy patients used general anaesthesia at the *RS UKI Jakarta* from January 2017 - August 2019 ?; c) How many male and female used spinal anaesthesia during appendectomy surgery at *RS UKI Jakarta* from January 2017 - August 2019 ?; d) How many male and female used general anaesthesia during appendectomy surgery at *RS UKI Jakarta* from January 2017 - August 2019 ?; e) How many uses of spinal and general anaesthesia are appendectomy patients based on age at *RS UKI Jakarta* from January 2017 - August 2019? Where the purpose of this research are: a) To determine the number of uses of spinal anaesthesia with general anaesthesia in appendectomy patients based on the age of the patient at the

RS UKI Jakarta from January 2017 - August 2019, and b) To determine the number of comparisons between the use of spinal anaesthesia with general anaesthesia in Appendectomy patients based on the gender of the patient at the *RS UKI Jakarta* from January 2017 - August 2019.

2. LITERATURE REVIEW

The appendix is a part of the large intestine that looks like a worm, in Latin, it is called the appendix vermiformis, located in the right iliac fossa region at the point of Mc Bourney or one-third of the line drawn from the right anterior iliac spine to the umbilicus. The length of the appendix varies, from 8-10 cm (mean 2- 20 cm) [14; 15]. The appendix is supplied by the appendicular artery originating from the ileocolic artery. Blood from the cecum and appendix flows through the ileocolic veins to the superior mesenteric veins. Lymphatic vessels from the cecum and appendix are drained through the lymph nodes in mesoappendix and the lymph nodes in the ileocolic which are along the ileocolic arteries. Efferent lymphatic vessels pass through the superior mesenteric lymph nodes. The innervation of the cecum and appendix originates from the sympathetic and parasympathetic nerves of the superior mesenteric plexus [16; 17].

Over the years, the appendix was recognized as a functionless remnant organ. However, it is now known that the appendix is an immunologic organ that actively participates in secreting immunoglobulins, mainly immunoglobulin A (Ig A) [18; 19]. Ig A is a secretor immunoglobulin that is very effective as a protection against infection and is produced by GALT (Gut Associated Lymphoid Tissue) which is present along the digestive tract, including the appendix. However, removal of the appendix does not affect the immune system because the amount of lymphoid tissue in the appendix is tiny compared to the amount in the gastrointestinal tract and throughout the body [20; 21; 22]. The appendix produces mucus 1-2ml / day. Under normal circumstances, mucus is secreted into the lumen and flows into the cecum. The inhibition of mucus flow in the mouth of the appendix plays a role in the pathogenesis of appendicitis [23]. The normal lumen pressure of the appendix reaches 60 cmH₂O [24; 25; 26].

Appendicitis is a bacterial infection. Various things play a role as a triggering factor, but obstruction of the appendix lumen is a factor proposed as a trigger in addition to lymphoid tissue hyperplasia, appendix tumours, and Ascaris worms that can cause a blockage. Appendicitis can occur at any age but rarely occurs in late adulthood and toddlers, the incidence of appendicitis increases in adolescence and adulthood. The age of 20-30 years can be categorized as a productive age; people who are at that age do many activities. It causes the person to ignore the nutrition of the food they consume. As a result, there is difficulty defecating, which will

cause increased pressure on the intestinal cavity and ultimately lead to blockage of the appendix tract [27; 28; 29]. The risk of sex in the incidence of appendicitis was mostly male, with a percentage of 72.2%, while female was only 27.8% [30]. It is because men spend more time outside the home to work and are more likely to consume fast food, so this can cause several complications or intestinal obstruction that can cause problems in the digestive system, one of which is appendicitis [31; 32].

Appendicitis is a bacterial infection. Various things play a role as a triggering factor, but obstruction of the appendix lumen is a factor proposed as a trigger in addition to lymphoid tissue hyperplasia, appendix tumours, and Ascaris worms that can cause a blockage. Another cause that is thought to cause appendicitis is the erosion of appendix mucosa due to parasites such as *E. histolytica*. Epidemiological research shows the role of eating low-fibre foods in influencing constipation which results in appendicitis. Constipation will increase intraluminal pressure, which results in functional obstruction of the appendix and increased germ growth [33]. Appendicitis has a characteristic combination of symptoms, which consist of nausea, vomiting and severe pain in the lower right abdomen. The pain usually starts suddenly in the upper abdomen or around the navel, then causes nausea and vomiting. After several hours, nausea disappeared, and the pain moved to the lower right stomach. If the doctor presses on this area, the patient will feel dull pain, and if this pressure is released, the pain can get sharper. Fever can reach 37, 8-38, 3⁰C. If the appendix ruptures, pain and fever can be severe. Worsening infection can cause shock.

Acute appendicitis is usually caused by blockage of the appendix lumen which can be caused by fecolith/appendicolith, lymphoid hyperplasia, foreign bodies, parasites, neoplasms, or strictures due to fibrosis due to previous inflammation. Lumen obstruction that occurs supports the development of bacteria and mucus secretion, causing lumen distension and increased lumen wall pressure. Increased pressure will inhibit lymph flow, causing edema, diapedesis of bacteria, and mucosal ulceration. At this time, there is acute focal appendicitis characterized by periumbilical pain. The continued mucus secretion and increasing pressure cause venous obstruction, perforated appendicitis, increased edema, and bacterial growth that causes inflammation, inflammation that occurs extends and affects the local peritoneum causing pain in the lower right abdominal area. At this time acute suppurative appendicitis occurs. If then the arterial flow is interrupted, a gangrenous wall infarction will result. This stage is called gangrenous appendicitis which when fragile and breaks into perforated appendicitis. Although it varies, perforation usually occurs at least 48 hours after the onset of symptoms. If all of the above processes are carried out with sufficiently good immunity, the omentum and the adjacent intestine will move towards the appendix as a defence mechanism, causing a local mass called the appendicular infiltrates. The inflammation that

occurs, can become abscessed or disappear. In children, the omentum is shorter, and the appendix is longer with thinner walls so that it becomes easy to perforate. Whereas in the elderly, perforation quickly occurs because there are blood vessel disorders [34; 35].

The diagnosis can be made through history, physical examination, and investigations. History - appendicitis should be presumed as a differential diagnosis in all patients with acute abdominal pain consistent with the above clinical manifestations of initial nausea and vomiting, followed by progressive lower right quadrant abdominal pain. Physical examination Patients with acute appendicitis appear painful and lying down with fever not too high on abdominal examination can find decreased / absent bowel sounds, tenderness and pain (Blumberg sign) focal in the appendix area called McBurney's point (the distal third of the line between the umbilicus right anterior superior iliac spinal). Peritoneal irritation is characterized by muscular defences, percussion, or loose pain. Appendicitis investigations: a) Laboratory tests-Mild leukocytosis (10,000-20,000 / uL) with an increase in the number of neutrophils. High leukocytosis (> 20,000 / uL) is obtained when perforation and gangrene have occurred. Urinalysis can be performed to differentiate between kidney and urinary tract abnormalities. At the time of acute appendicitis, ketonuria was found. In women, a pregnancy test should be checked if an ectopic pregnancy is suspected as a differential diagnosis, and b) Ultrasound can be used with the finding of an appendicitis anteroposterior diameter greater than 7mm, wall thickening, incompressible lumen structure (target lesion), or the presence of an appendicolith [36; 37].

Management of appendicitis: a) Pre-operative - Close observation, bed rest, and fasting. Abdominal and rectal examinations as well as blood tests, may be repeated periodically. Abdominal and chest radiographs may be taken to look for other complications. Broad-spectrum intravenous antibiotics and analgesics can be given. In appendix perforation it is necessary to provide fluid resuscitation before surgery; b) Operative - 1) Open appendectomy - performed with a transverse incision in the right lower quadrant (Davis-Rockey) or an oblique incision (McArthur-McBurney). In the unclear diagnosis a sub-umbilical incision in the midline can be performed; 2) Laparoscopic appendectomy - surgical technique with less wound and infection chances, and c) Post-operative - It is necessary to observe vital signs in anticipation of bleeding in shock, hyperthermia, or respiratory distress. The patient is placed in the fowler position and for 12 hours fasting first in surgery with perforation or generalized peritonitis, fasting is performed until bowel function returns to normal. Gradually the patient was given drinking, filtered food, soft food, and regular food [38; 39]. Appendectomy is a surgical procedure to cut and remove the appendix. Most of these procedures are performed in an emergency to treat appendicitis or appendicitis [40]. The conventional or open method of surgery is done by making an incision in the lower

right abdomen. The incision is less than 3 inches (7.6 cm) long. The surgeon then identifies all the organs in the stomach and checks for any organ abnormalities or other diseases. The location of the appendix is drawn to the open part. The surgeons separate the appendix from all surrounding tissue and place it on the cecum and then remove it. The tissue where the appendix was attached earlier, namely the cecum, is closed and inserted back into the stomach. The muscle and skin layers are then sutured [41].

General anaesthesia is a state of pain relief throughout the body and temporary loss of consciousness that results from suppression of the central nervous system due to pharmacological induction or sensory compression of the nerves. General anaesthetic agents work by reversibly suppressing the central nervous system (CNS). General anaesthesia is a condition controlled by reversible unconsciousness and is obtained through the use of drugs by injection and or inhalation which is characterized by loss of pain response (analgesia), memory loss (amnesia), loss of response to stimuli or reflexes and loss of spontaneous motion (immobility), and loss of consciousness (unconsciousness) [42]. Anaesthesia has been given to more than 75 million surgery patients in the world every year. Anaesthesia can be divided into three phases, namely the induction phase, maintenance and regaining consciousness from anaesthesia. The ideal anaesthesia can produce anaesthesia quietly and quickly and allows recovery as soon as treatment is complete [38; 41].

Spinal anaesthesia is regional analgesia by blocking nerve cells in the subarachnoid space by local anaesthetic drugs. This anaesthetic technique has become popular because it is considered simple and effective, safe for the nervous system. The concentration of the drug in plasma is not dangerous. It has several advantages, including intense analgesia levels, the patient remains conscious, adequate muscle relaxation, less surgical wound bleeding, the risk of aspiration of a patient with a full stomach is smaller, and the recovery of gastrointestinal function is faster. Spinal anaesthesia creates a temporary barrier to nerve transmission of the subarachnoid space as a result of the injection of a local anaesthetic into the cerebrospinal fluid. Several names of spinal anaesthetics have been introduced, including spinal analgesia, analgesia subarachnoid, spinal block, arachnoid block, subarachnoid and lumbar anaesthesia [42]. Preparations for spinal anaesthesia, these are preparations for spinal anaesthesia like those for general anaesthesia. The area around the puncture site is examined whether it will cause difficulties, for example, there is an anatomical abnormality of the spine, or the patient is so obese that he cannot feel the protrusion of the spinous process.

3. METHOD

The research design chosen for this study is a retrospective case study. The research data were taken from secondary data in the form of medical records of patients undergoing appendectomy surgery. The research results will be presented in a descriptive-analytic form. This research was conducted at the *Rumah Sakit Umum Universitas Kristen Indonesia (RSU-UKI) Jakarta*. The population in this study was all appendectomy patients who used spinal anaesthesia with general anaesthesia at the *RS UKI Jakarta* from January 2017 - August 2019 who had complete data and included the inclusion criteria. The research sample was taken based on total sampling based on inclusion and exclusion criteria. This study uses bivariate data analysis and will be processed with the help of Microsoft Excel.

4. RESULT AND DISCUSSION

After collecting data by tracing the medical records of appendectomy patients at the *RS UKI* from January 2017 to August 2019, the following results were obtained:

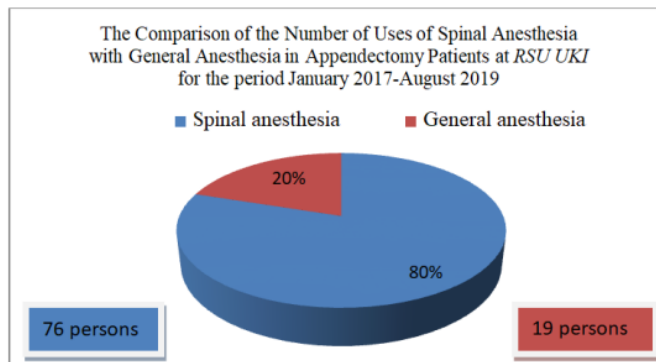


Figure 1 A comparison Diagram of the Use of Spinal Anaesthesia with General Anaesthesia in Appendectomy Patients at the RS UKI Jakarta from January 2017-August 2019

Based on Figure 1, from the results of the study, the number of users of spinal anaesthesia with general anaesthesia in appendectomy patients was 95 persons. Seventy-six persons (80%) used spinal anaesthesia, and 19 persons (20%) used general anaesthesia.

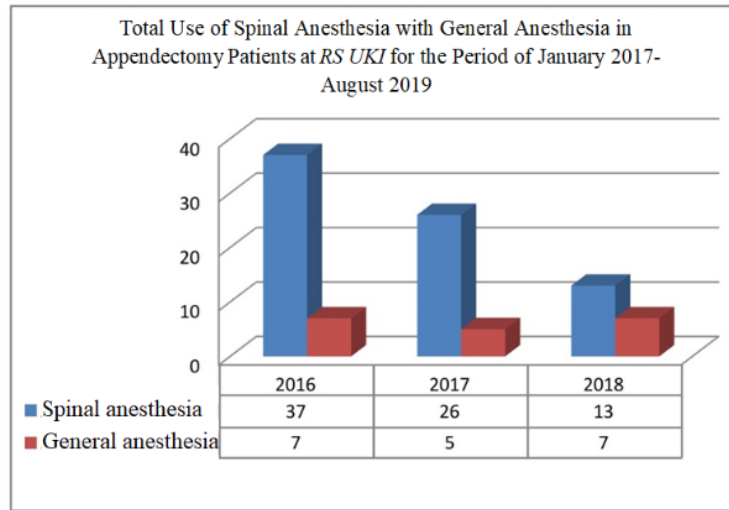


Figure 2 Comparison Diagram of the Use of Spinal Anaesthesia with General Anaesthesia in Appendectomy Patients from January 2017-August 2019

Based on Figure 2, from the results of research in 2016, the use of spinal anaesthesia totalled 37 people, and the use of general anaesthesia amounted to 7 people, in 2017 the use of spinal anaesthesia amounted to 26 people and the use of general anaesthesia amounted to 5 people, in 2018 the use of spinal anaesthesia amounted to 13 people and the use of general anaesthesia amounted to 7 people.

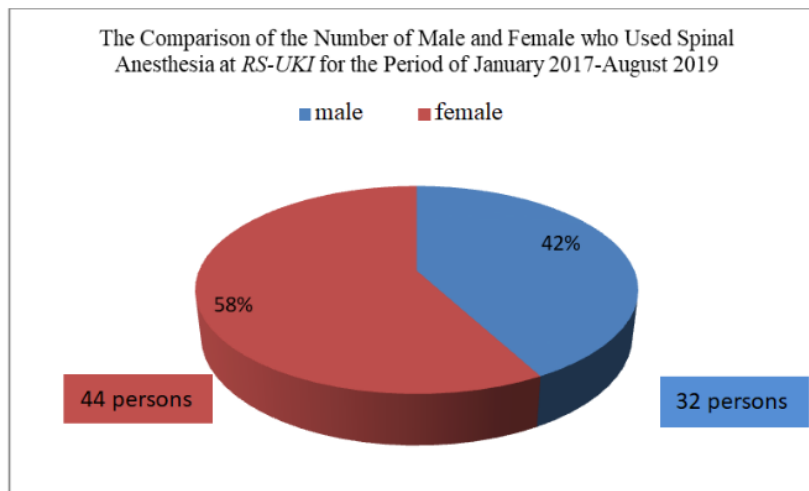


Figure 3 Diagram of the Comparison of the Number of Male and Female Who Used Spinal Anaesthesia from January 2017-August 2019

Based on Figure 3, the number of men who used spinal anaesthesia was 32 (42%), and the number of women who used spinal anaesthesia was 44 (58%).

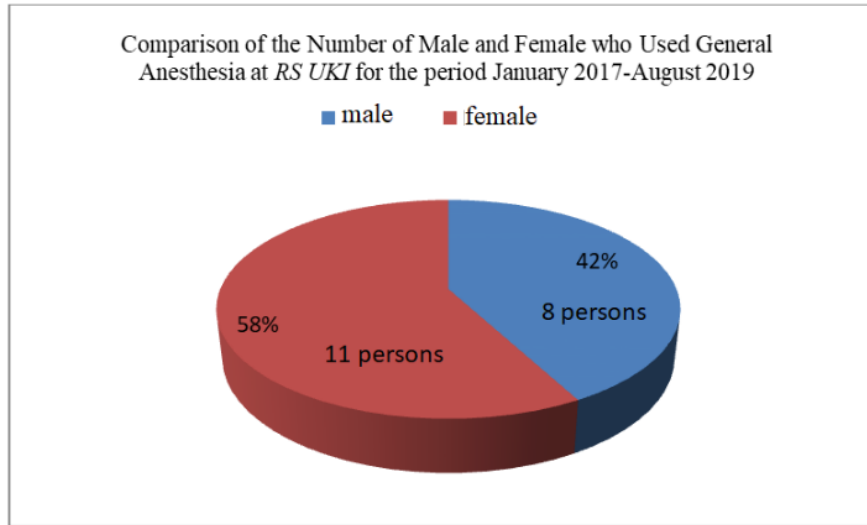


Figure 4 Comparison of the Number of Male and Female Who Used General Anaesthesia for the Period January 2017-August 2019

Based on Figure 4, the number of men using general anaesthesia amounted to 8 people (42%), and the number of women who used general anaesthesia amounted to 11 people (58%).

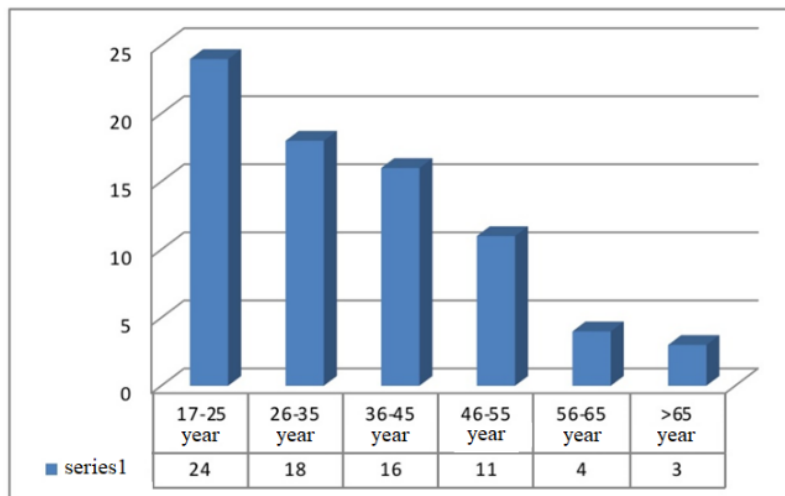


Figure 5 Comparison Diagram Based on the Age of Use of Spinal Anaesthesia in Appendectomy Patients for the Period of January 2017 - August 2019.

Based on Figure 5, the use of spinal anaesthesia at the age of 17-25 years is 24 people, aged 26-35 years are 18 people, aged 36-45 years are 16 people, aged 46-55 years are 11 people, aged 56-65 years are four people and over 65 years amounting to 3 people.

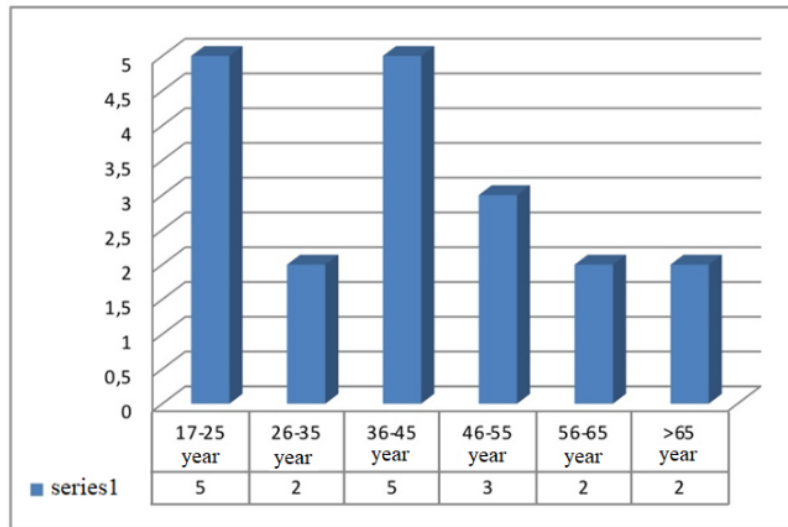


Figure 6 Comparison Diagram Based on the Age of Use of General Anaesthesia in Appendectomy Patients for the Period January 2017-August 2019

Based on Figure 6, 5 people use general anaesthesia at the age of 17-25 years, two people aged 26-35 years, five people aged 36-45 years, three people aged 46-55 years, 56-65 years old total two people and over 65 years of age are two people.

From this study it can be concluded that the use of spinal anaesthesia in appendectomy patients is more widely used, namely 76 people (80%), compared to the use of general anaesthesia amounted to 19 people (20%). Spinal anaesthesia is more widely used in appendectomy patients because of the following factors: a) Theoretically the indication for the use of spinal anaesthesia is the lower extremities in the pelvic area, perineum and lower abdomen [25]; b) While the operation for appendicitis patients is performed on the lower abdomen; c) The use of spinal anaesthesia is more indicated in operations that are not more than 2 hours long. According to the data taken from the medical records of the *RS UKI* when performing an appendectomy operation, the average time needed only about 2 hours. Recent studies have shown that regional anaesthetic techniques also have positive effects on patient outcomes such as reducing the inflammatory response, improving bowel function, and coagulation factors [27]. From the total cost, that spinal anaesthesia is cheaper than general anaesthesia, and the Spinal anaesthesia is safer for patients who are not fasting/performing emergency surgery. According to the data that researchers got at the *RS UKI Jakarta* from January 2017-August 2019, the number of cito surgery in appendectomy patients is relatively high, namely 44 out of 95 patients.

From the results of research at the *RS UKI Jakarta* from January 2017 - August 2019, the number of appendectomy patients who used spinal anaesthesia was more

female, namely 44 (58%) and 32 men (42%). The number of appendectomy patients who used general anaesthesia was 11 female (58%) and eight male (42%). It can be concluded that appendectomy patients who use spinal anaesthesia and who use general anaesthesia in appendectomy patients are more female than male. Based on the prevalence theory, there are more men than women. However, based on the data the researchers got at the *RS UKI Jakarta* from January 2017-August 2019, there were more female patients than men. It may be because the number of female patients who come for treatment is more than that of men at the *RS UKI Jakarta*. From the results of research at the *RS UKI Jakarta* from January 2017 - August 2019, those appendectomy patients who use spinal anaesthesia and general anaesthesia are more at the age of 17-25 years.

5. CONCLUSION

So it can be concluded that the use of spinal anaesthesia is more widely used than general anaesthesia in appendectomy patients at the *RS UKI Jakarta* from January 2017 - August 2019. Based on gender, the use of spinal anaesthesia with general anaesthesia is more for women than for men 17-25 years old. From the results of this study, spinal anaesthesia is recommended for appendectomy patients. The results of this study can be used in future studies to find out why spinal anaesthesia is more widely used.

REFERENCES

- [1] Hariprasad, S. M., Mieler, W. F., Lin, T. K., Sponsel, W. E., & Graybill, J. R. (2008). Voriconazole in the treatment of fungal eye infections: a review of current literature. *British Journal of Ophthalmology*, 92(7), 871-878.
- [2] Piepoli, M. F., Hoes, A. W., Agewall, S., Albus, C., Brotons, C., Catapano, A. L., ... & Graham, I. (2016). 2016 European Guidelines on cardiovascular disease prevention in clinical practice: The Sixth Joint Task Force of the European Society of Cardiology and Other Societies on Cardiovascular Disease Prevention in Clinical Practice (constituted by representatives of 10 societies and by invited experts) Developed with the special contribution of the European Association for Cardiovascular Prevention & Rehabilitation (EACPR). *European heart journal*, 37(29), 2315-2381.
- [3] Alsharief, A. N., Laxer, R. M., Wang, Q., Stimec, J., Man, C., Babyn, P., & Doria, A. S. (2020). Monogenic autoinflammatory diseases in children: single center experience with clinical, genetic, and imaging review. *Insights into Imaging*, 11(1), 1-24.

- [4] Sulaiman, E., & Nurcahya, S. The Role of Nurses in Reducing the Anxiety Level of Pre-Appendectomy Patients at Bahteramas General Hospital, Southeast Sulawesi Province.
- [5] Siswoyo, C. Y. P., & Murtaqib, K. R. M. N. (2015). Effect of Early Mobilization on the Change of Pain Level in Clients With Post Appendectomy at Mawar Surgical Room of Baladhika Husada Hospital Jember Regency. *Hospital*, (8).
- [6] Wijaya, A. I., Dewi, A., & Listiowati, E. (2017). Appendicitis Clinical Pathway Implementations Compliance Evaluation in Hospital.
- [7] Zhafira, T., Yulianti, H., & Wastaman, M. (2017). Histopathologic Distribution of Appendicitis at Dr. Hasan Sadikin General Hospital, Bandung, Indonesia, in 2012. *Althea Medical Journal*, 4(1), 36-41.
- [8] Raveenthiran, V. (2015). Neonatal appendicitis (part 1): a review of 52 cases with abdominal manifestation. *Journal of neonatal surgery*, 4(1).
- [9] Raveenthiran, V. (2015). Neonatal appendicitis (part 1): a review of 52 cases with abdominal manifestation. *Journal of neonatal surgery*, 4(1).
- [10] Zachariah, S. K., Fenn, M., Jacob, K., Arthungal, S. A., & Zachariah, S. A. (2019). Management of acute abdomen in pregnancy: current perspectives. *International Journal of Women's Health*, 11, 119.
- [11] Ross, A., & LeLeiko, N. S. (2010). Acute abdominal pain. *Pediatrics in review*, 31(4), 135.
- [12] Wang, J., Zhou, Y., Zhang, Z. F., Li, C. Q., Zheng, W. J., & Liu, J. (2011). Minimally invasive or open transforaminal lumbar interbody fusion as revision surgery for patients previously treated by open discectomy and decompression of the lumbar spine. *European Spine Journal*, 20(4), 623-628.
- [13] Chin, K. R. (2011). *U.S. Patent No. 7,955,355*. Washington, DC: U.S. Patent and Trademark Office.
- [14] Daniel Ravikumar, R. (2017). *Follow Up of treated cases of Appendicular Mass and Abscess and Ascertaining the role of Interval Appendicectomy* (Doctoral dissertation, Madras Medical College, Chennai).
- [15] Jessima Subahani, K. (2013). *Comparison of Histopathology in Emergency and Delayed Appendicectomy Specimens* (Doctoral dissertation, Stanley Medical College, Chennai).
- [16] Thorsen, Y., Stimec, B., Andersen, S. N., Lindstrom, J. C., Pfeffer, F., Oresland, T., ... & RCC Study Group. (2016). Bowel function and quality of life after superior mesenteric nerve plexus transection in right colectomy with D3 extended mesenterectomy. *Techniques in coloproctology*, 20(7), 445-453.
- [17] Shoja, M. M., Sharma, A., Mirzayan, N., Groat, C., Watanabe, K., Loukas, M., & Shane Tubbs, R. (2013). Neuroanatomy of the female abdominopelvic region: a review with application to pelvic pain syndromes. *Clinical Anatomy*, 26(1), 66-76.

- [18] Demas, G. E., Zysling, D. A., Beechler, B. R., Muehlenbein, M. P., & French, S. S. (2011). Beyond phytohaemagglutinin: assessing vertebrate immune function across ecological contexts. *Journal of Animal Ecology*, 80(4), 710-730.
- [19] Huber, V., Camisaschi, C., Berzi, A., Ferro, S., Lugini, L., Triulzi, T., ... & Rivoltini, L. (2017, April). Cancer acidity: An ultimate frontier of tumor immune escape and a novel target of immunomodulation. In *Seminars in cancer biology* (Vol. 43, pp. 74-89). Academic Press.
- [20] Girard-Madoux, M. J., de Agüero, M. G., Ganal-Vonarburg, S. C., Mooser, C., Belz, G. T., Macpherson, A. J., & Vivier, E. (2018, April). The immunological functions of the Appendix: An example of redundancy?. In *Seminars in immunology* (Vol. 36, pp. 31-44). Academic Press.
- [21] Laurin, M., Everett, M. L., & Parker, W. (2011). The cecal appendix: one more immune component with a function disturbed by post-industrial culture. *The Anatomical Record: Advances in Integrative Anatomy and Evolutionary Biology*, 294(4), 567-579.
- [22] Altinbas, A., Eken, G., Cetiner, D., Koca, E., Dundar, Z., & Haznedaroglu, I. (2011). Typhilitis of the appendix presenting as an acute appendicitis in acute myeloid leukemia. *The American Surgeon*, 77(2), 231-231.
- [23] Barapatre, Y. R., Agarwal, M. M., Mavuduru, R., Sharma, S. K., Kumar, S., Singh, S. K., & Mandal, A. K. (2014). Short-Term Functional and Urodynamic Outcome of W-ileal Orthotopic Neobladder with Serosa-Lined Tunneled Uretero-Ileal Anastomosis. *LUTS: Lower Urinary Tract Symptoms*, 6(1), 26-34.
- [24] Facchini, L., Bellin, A., & Toro, E. F. (2013). A new model of filtration and macromolecules transport across capillary walls. *arXiv preprint arXiv:1308.1271*.
- [25] Sinclair, M. (2011). The use of abdominal massage to treat chronic constipation. *Journal of bodywork and movement therapies*, 15(4), 436-445.
- [26] Nigam, Y., Knight, J., & Williams, N. (2019). Gastrointestinal tract 5: the anatomy and functions of the large intestine. *Nursing Times*, 115(10), 50-53.
- [27] Dumic, I., Nordin, T., Jecmenica, M., Stojkovic Lalosevic, M., Milosavljevic, T., & Milovanovic, T. (2019). Gastrointestinal tract disorders in older age. *Canadian Journal of Gastroenterology and Hepatology*, 2019.
- [28] Addabbo, T., Bastos, A., Casaca, S. F., Duvvury, N., & Ní Léime, Á. (2015). Gender and labour in times of austerity: Ireland, Italy and Portugal in comparative perspective. *International Labour Review*, 154(4), 449-473.
- [29] Erdoğan, D., Karaman, İ., Aslan, M. K., Karaman, A., & Çavuşoğlu, Y. H. (2013). Analysis of 3776 pediatric inguinal hernia and hydrocele cases in a tertiary center. *Journal of pediatric surgery*, 48(8), 1767-1772.
- [30] Carod-Artal, F. J. (2018). Infectious diseases causing autonomic dysfunction. *Clinical Autonomic Research*, 28(1), 67-81.

- [31] Veeranna, V., Pradhan, J., Niraj, A., Fakhry, H., & Afonso, L. (2010). Traditional cardiovascular risk factors and severity of angiographic coronary artery disease in the elderly. *Preventive cardiology*, 13(3), 135-140.
- [32] Principi, N., Marchisio, P., Rosazza, C., Sciarrabba, C. S., & Esposito, S. (2017). Acute otitis media with spontaneous tympanic membrane perforation. *European Journal of Clinical Microbiology & Infectious Diseases*, 36(1), 11-18.
- [33] Kuzmich, S., Howlett, D. C., Andi, A., Shah, D., & Kuzmich, T. (2009). Transabdominal sonography in assessment of the bowel in adults. *American Journal of Roentgenology*, 192(1), 197-212.
- [34] Cavalcoli, F., Zilli, A., Fraquelli, M., Conte, D., & Massironi, S. (2017). Small bowel ultrasound beyond inflammatory bowel disease: an updated review of the recent literature. *Ultrasound in Medicine & Biology*, 43(9), 1741-1752.
- [35] Chandon, P., & Wansink, B. (2012). Does food marketing need to make us fat? A review and solutions. *Nutrition reviews*, 70(10), 571-593.
- [36] Roberts, D., & Greenwood, M. (2008). *Practical food microbiology*. John Wiley & Sons.
- [37] Flum, D. R. (2015). Acute appendicitis—appendectomy or the “antibiotics first” strategy. *New England Journal of Medicine*, 372(20), 1937-1943.
- [38] Risselada, M., Mathews, K. G., & Griffith, E. (2016). The effect of specimen preparation on post-excision and post-fixation dimensions, translation, and distortion of canine cadaver skin-muscle-fascia specimens. *Veterinary Surgery*, 45(5), 563-570.
- [39] Andrews, P. L., Darmaillacq, A. S., Dennison, N., Gleadall, I. G., Hawkins, P., Messenger, J. B., ... & Smith, J. A. (2013). The identification and management of pain, suffering and distress in cephalopods, including anaesthesia, analgesia and humane killing. *Journal of Experimental Marine Biology and Ecology*, 447, 46-64.
- [40] Brown, E. N., Purdon, P. L., & Van Dort, C. J. (2011). General anesthesia and altered states of arousal: a systems neuroscience analysis. *Annual review of neuroscience*, 34, 601-628.
- [41] Gargiulo, S., Greco, A., Gramanzini, M., Esposito, S., Affuso, A., Brunetti, A., & Vesce, G. (2012). Mice anesthesia, analgesia, and care, Part I: anesthetic considerations in preclinical research. *ILAR journal*, 53(1), E55-E69.
- [42] Bajwa, S. J. S., & Kaur, J. (2013). Clinical profile of levobupivacaine in regional anesthesia: A systematic review. *Journal of anaesthesiology, clinical pharmacology*, 29(4), 530.

TurnitinTheComparisonoftheUseofSpinalAnesthesiawith

ORIGINALITY REPORT

15%

SIMILARITY INDEX

11%

INTERNET SOURCES

2%

PUBLICATIONS

5%

STUDENT PAPERS

PRIMARY SOURCES

1	repository.uki.ac.id Internet Source	5%
2	sehatselalujmbh.blogspot.com Internet Source	2%
3	Submitted to Universitas Jember Student Paper	2%
4	Submitted to Universitas Brawijaya Student Paper	1%
5	journals.sagepub.com Internet Source	1%
6	worldwidescience.org Internet Source	1%
7	archive.org Internet Source	1%
8	Submitted to Queen Mary and Westfield College Student Paper	<1%
9	Barlow, Andrew, Mitchel Muhleman, Jerzy Gielecki, Petru Matusz, R. Shane Tubbs, and	<1%

Marios Loukas. "The vermiform appendix: A review : The Vermiform Appendix", Clinical Anatomy, 2013.

Publication

10

Submitted to Deakin University

Student Paper

<1%

11

www.thefreelibrary.com

Internet Source

<1%

12

www.mysciencework.com

Internet Source

<1%

13

www.studyblue.com

Internet Source

<1%

14

Emmanouil Korakas, George Dimitriadis, Athanasios Raptis, Vaia Lambadiari. "Dietary Composition and Cardiovascular Risk: A Mediator or a Bystander?", Nutrients, 2018

Publication

<1%

Exclude quotes On

Exclude matches Off

Exclude bibliography On