

Periode Kepaniteraan	Nama Mahasiswa	NIM	Pembimbing	Ket
25 Februari 2019 – 30 Maret 2019	Ajeng Damarianti	1765050297	Dr.dr. Ago Harlim, MARS, Sp.KK	
	Oditho Ananta Prawira	1865050020	Dr.dr. Ago Harlim, MARS, Sp.KK	
1 April 2019 – 4 Mei 2019	Adinda Devi Octaviani	1765050211	Dr.dr. Ago Harlim, MARS, Sp.KK	
	Olivia Stella Simbolon	1865050027	Dr.dr. Ago Harlim, MARS, Sp.KK	
6 Mei 2019 – 15 Juni 2019	Kenny Yose Yimisesla	1765050133	Dr.dr. Ago Harlim, MARS, Sp.KK	
	Hana Rosyana Puspita	1765050114	Dr.dr. Ago Harlim, MARS, Sp.KK	
17 Juni 2019 – 20 Juli 2019	Sarahlia P. M. Blegur	1865050045	Dr.dr. Ago Harlim, MARS, Sp.KK	
	Benedikta Suryandari	1765050382	Dr.dr. Ago Harlim, MARS, Sp.KK	
22 Juli 2019 -24 Agustus 2019	Sarah Nova Gradiska	1865050044	Dr.dr. Ago Harlim, MARS, Sp.KK	
24 Agustus 2019 – 26 September 2019	Rega Setya Abeto Marko	1965050084	Dr.dr. Ago Harlim, MARS, Sp.KK	
4 November 2019 – 7 Desember 2019	Ereis Valentina	1965050027	Dr.dr. Ago Harlim, MARS, Sp.KK	

Dr ago harlim, MARS, SpKK

Pioderma

Definisi

Radang kulit oleh bakteri pembuat nanah

Etiologi

Streptococcus β hemolyticus, Staphylococcus aureus/albus

Corynebacterium minutissimum

Gram negatif

Faktor predeposisi

- Higiene yang kurang
- Daya tahan tubuh menurun
- Telah ada penyakit lain di kulit

- Klasifikasi : primer
 sekunder

Pioderma primer

- E/ *Staphylococcus*
Impetigo kontagiosa bulosa
Folikulitis, furunkel, karbunkel
Sycosis barbae, staphylococcal scalded skin syndrome, abses multiple kel keringat
- E/ *Streptococcus* impetigo kontagiosa
krustosa, ektima, eriseplas
- E/ Keduanya : selulitis
- E/ *Corynebacterium minutissimum*: eritrasma

Pioderma sekunder

Sudah ada penyakit lain

- Eczema vulgaris impetigenisata
- Prurigo impetigenisata
- Varisela impetigenisata
- Hidradenitis suppurativa
- Intertrigo
- ulkus

Impetigo kontagiosa bulosa/ neonatorum

- Bula dinding tipis berisi nanah ,
menggelantung /hipopion
- Pecah , erosi tu daerah tertutup
- Dd/TEN

Impetigo kontagiosa krustosa

- Mulai dari leher, muka ekstermitas
- Makula eritematosa, vesikel, bula, pecah, seropurulen,krusta.
- Krusta dilepas erosi, girata
- Ditularkan melalui jari jari, handuk
- Komplikasi : gromerulonefritis (strep group A serotipe 2)

Ektima

- Anak anak , tu krn jatuh
- Tungkai, bokong
- Vesikopustul,krusta, lepas ulkus berbentuk cawan , tepi meninggi
- Bisa jadi gangren
- Predeposisi: DM, malnutrisi
- Dd/ karbunkel

Folikulitis, furunkel, karbunkel

- Karbunkel superfisial
- Karbunkel profunda:
benjolan, perforasi abses, ulkus tidak teratur,
tepi menonjol, sembuh jadi sikatrik

Eritrasma

- *E/Corynebacterium minutissimum*
- Lipatan kulit, makula merah keciklatan, atau plakat, tidak teratur, batas tegas, skuama halus diatasnya.
- Lampu wood
- DD/
- Terapi/ eritromisin

Erisipelas, selulitis, gangren

- Gejala konstitusi
- Biasanya didahului trauma
- Kulit eritem batas tegas, pinggir meninggi , dgn tanda radang akut. Dapat disertai vesikel, bula
- Selulitis : subkutan
- Flegmon: supurasi
Th/ eksisi

Pionikia

- Radang sekitar kuku
- Bisa *Staphylococcus aureus* dan atau *Streptococcus β hemolitycus*
- Trauma, abses subungual
- Terapi : jk abses ekstraksi kuku

Abces multiple kelenjar keringat

- Sering bersamaan dgn miliaria

Gk/ nodul eritematosa, multiple, tdk nyeri, kubah, memecah

Lokasi/ daerah keringat

Dd/ furunkolosis lebih nyeri

Staphylococcal scalded skin syndrome

- Terutama pada anak < 5 thn, ginjal
- E/ *Staphylococcus aureus* group 2 faga 52, 55, dan atau 71 , eksotoksin epidermolisis
- Eritema mendadak, mulai dari lipatan 24jam menyeluruh, 24-48jam bula dinding kendur, Nikolsky positif, 2-3hari pengeriputan , lembaran lembaran kulit. Deskuamasi .
- Mukosa jarang kena

Komplikasi: Pneumonia, septikemia

- Pemeriksaan bakteriologi
- Histologi
- Dd/ NET

Terapi

- Lokal : kering, basah
- Sistemik :
- Klindamisin, lincomicin
- Eritromisin 4x500mg
- Sefalosporin generasi 1
- Kloksasilin, diklosasilin

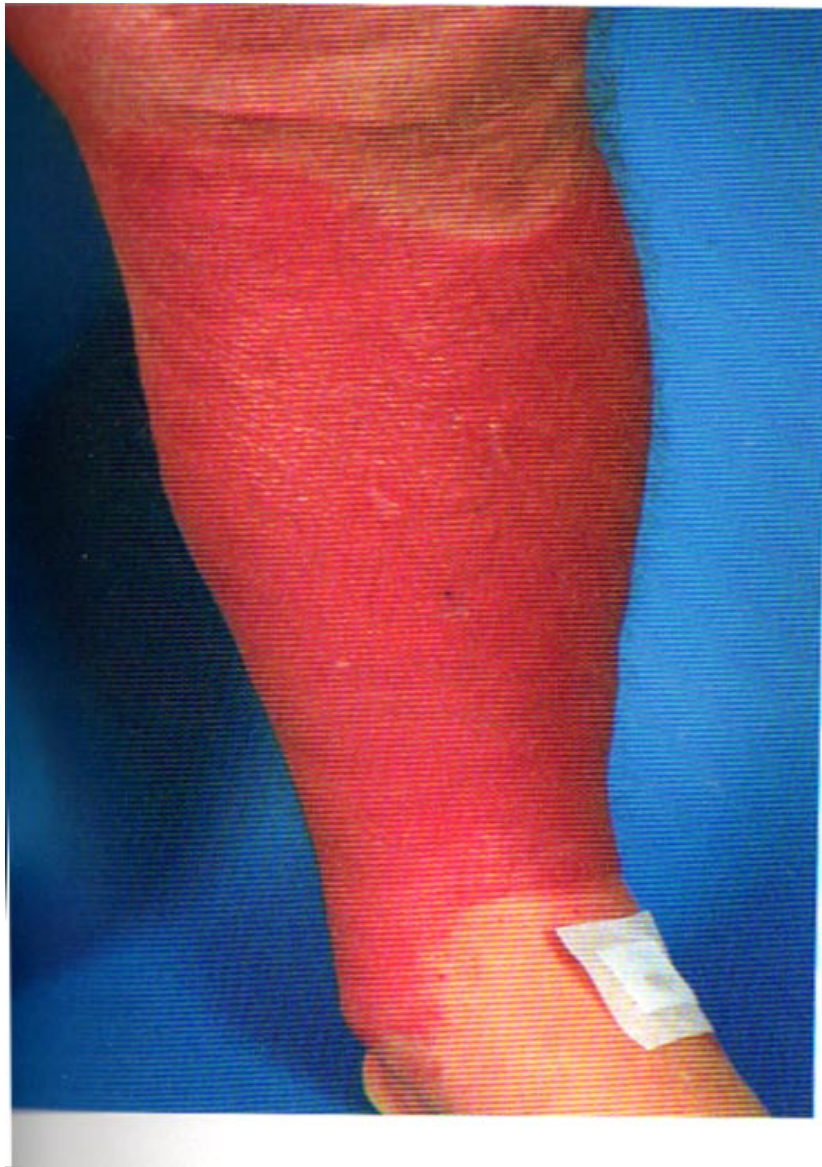

FIGURE 22-22 Erysipelas of leg: *S. aureus*
The lower leg is red, hot, tender, and edematous. Erythematous plaque is well defined. The infection is recurrent with interdigital tinea pedis as the portal of entry.

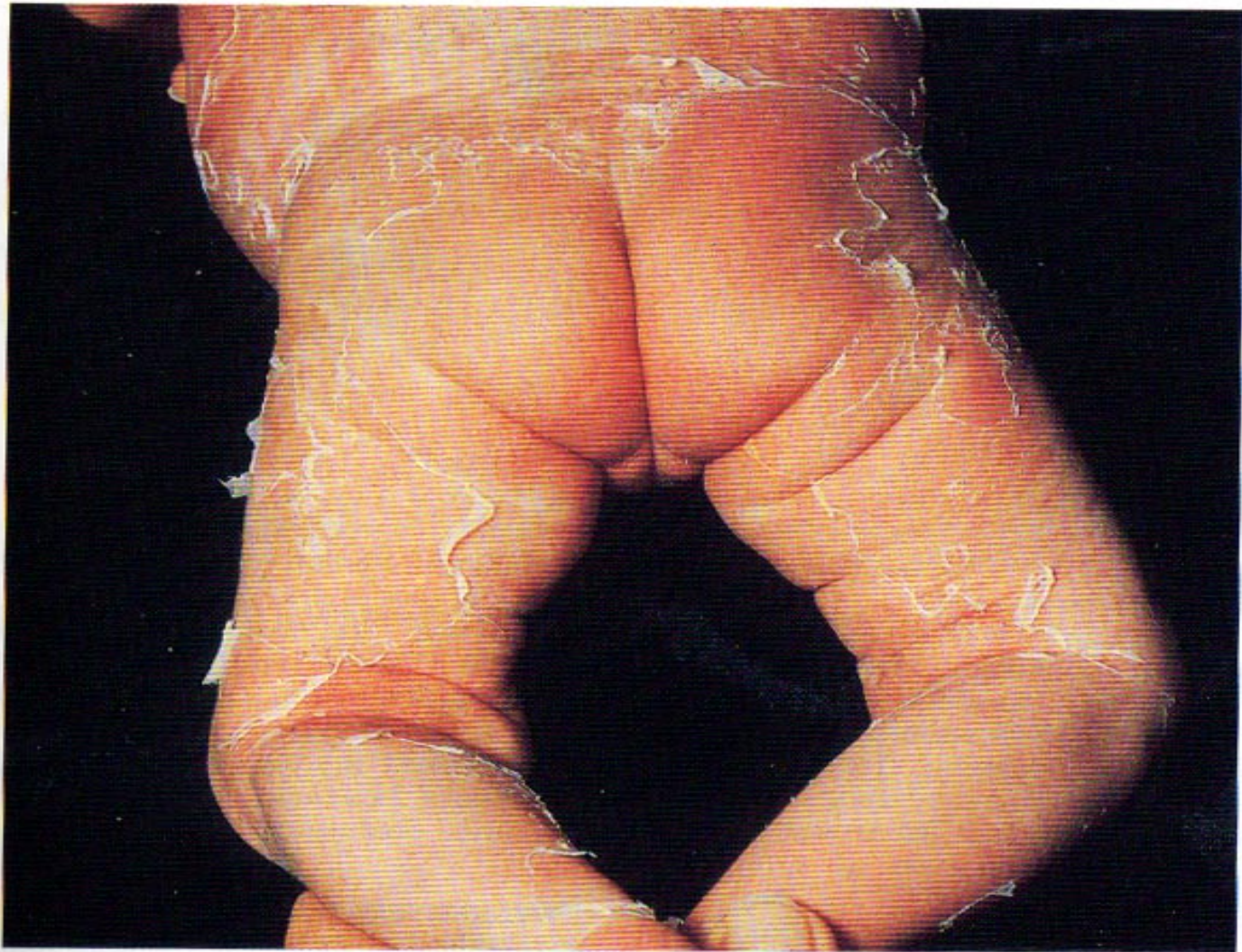

FIGURE 22-33 Staphylococcal scalded-skin syndrome *Generalized desquamation following SSSS in an infant.*

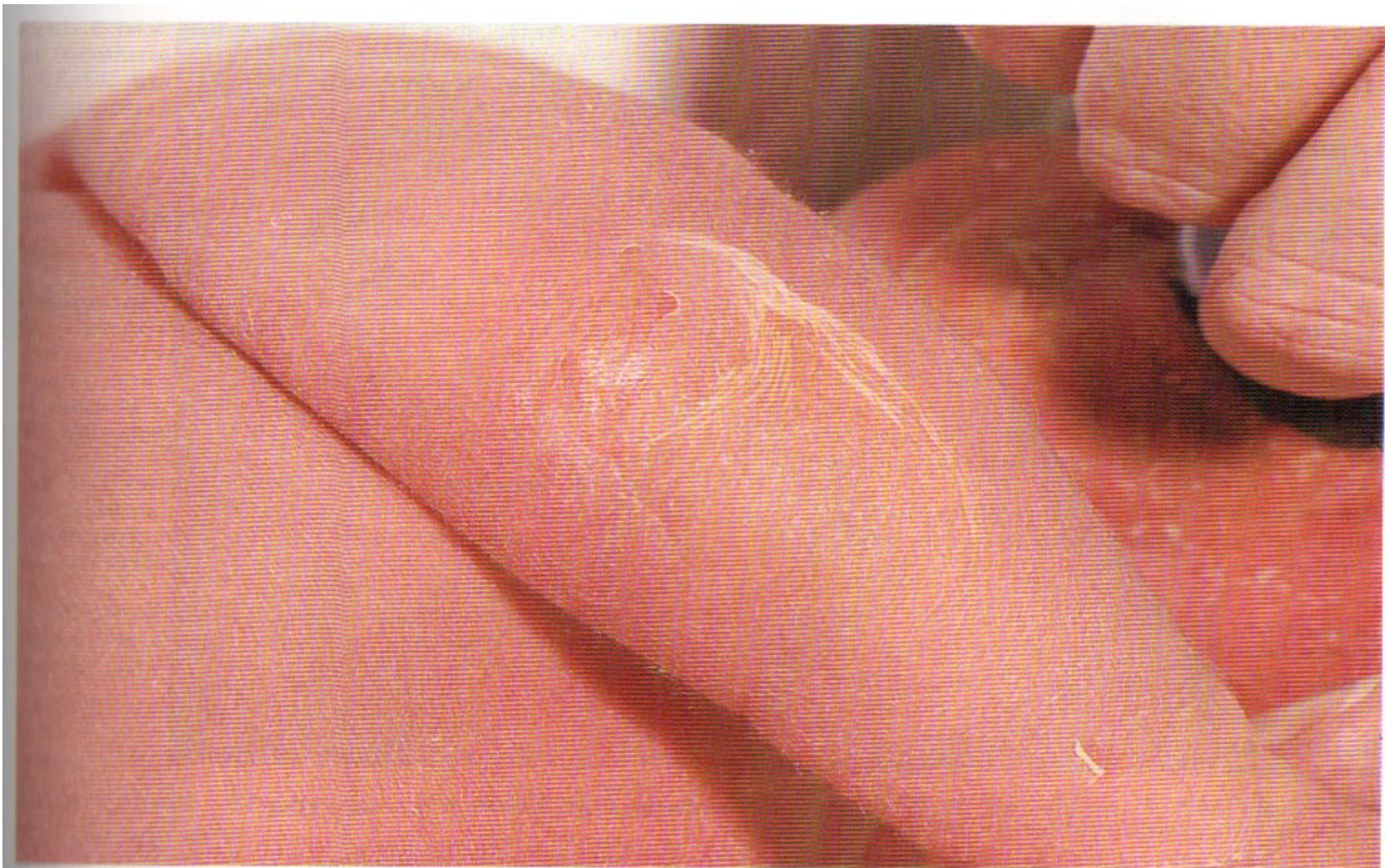


FIGURE 22-31 Staphylococcal scalded-skin syndrome *The skin of this infant is diffusely erythematous; gentle pressure to the skin of the arm has sheared off the epidermis, which folds like tissue paper.*

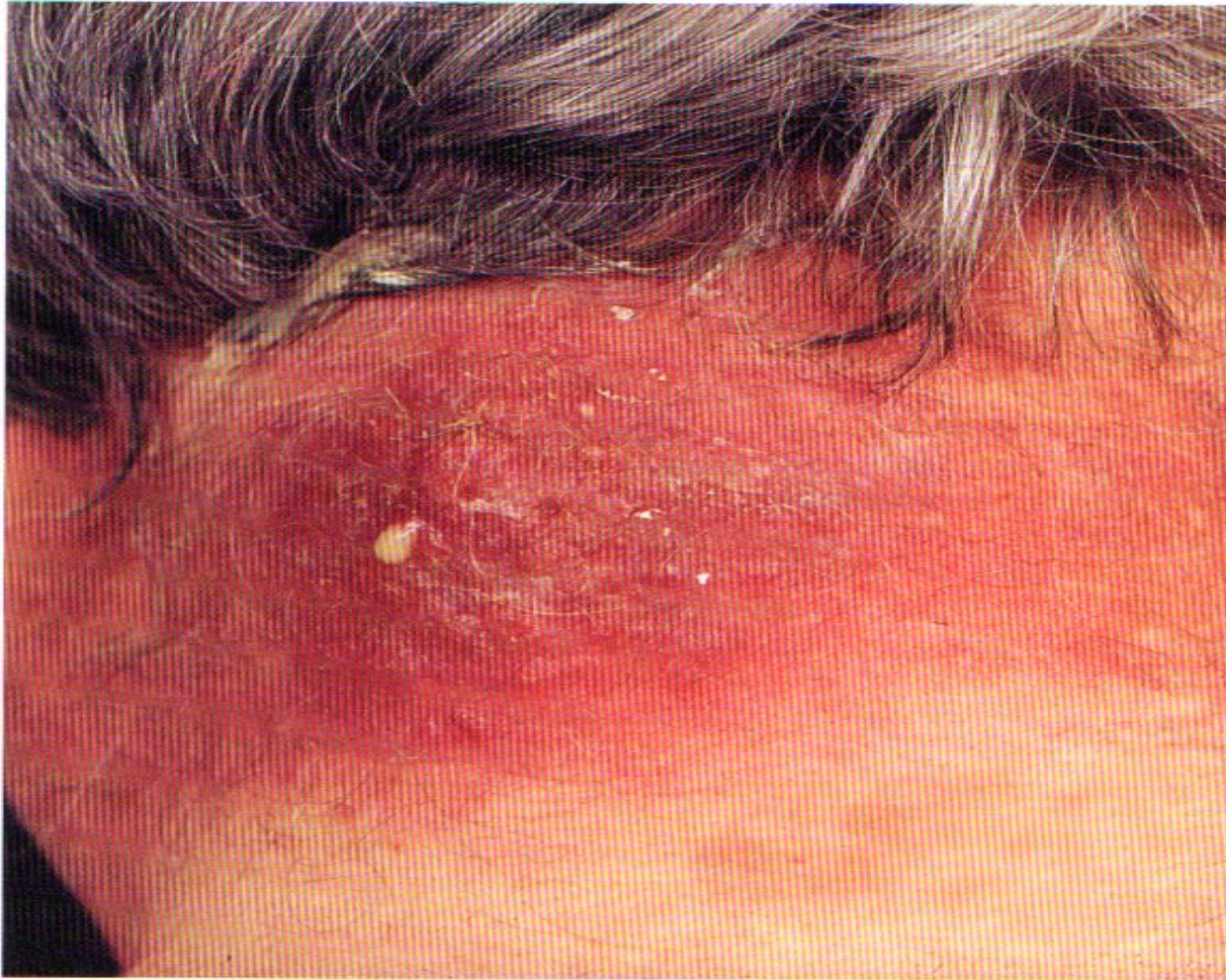

FIGURE 22-19 Carbuncle: *S. aureus* *A very large, inflammatory plaque studded with pustules, draining pus, on the nape of the neck. Infection extends down to the fascia and has formed from a confluence of many furuncles.*

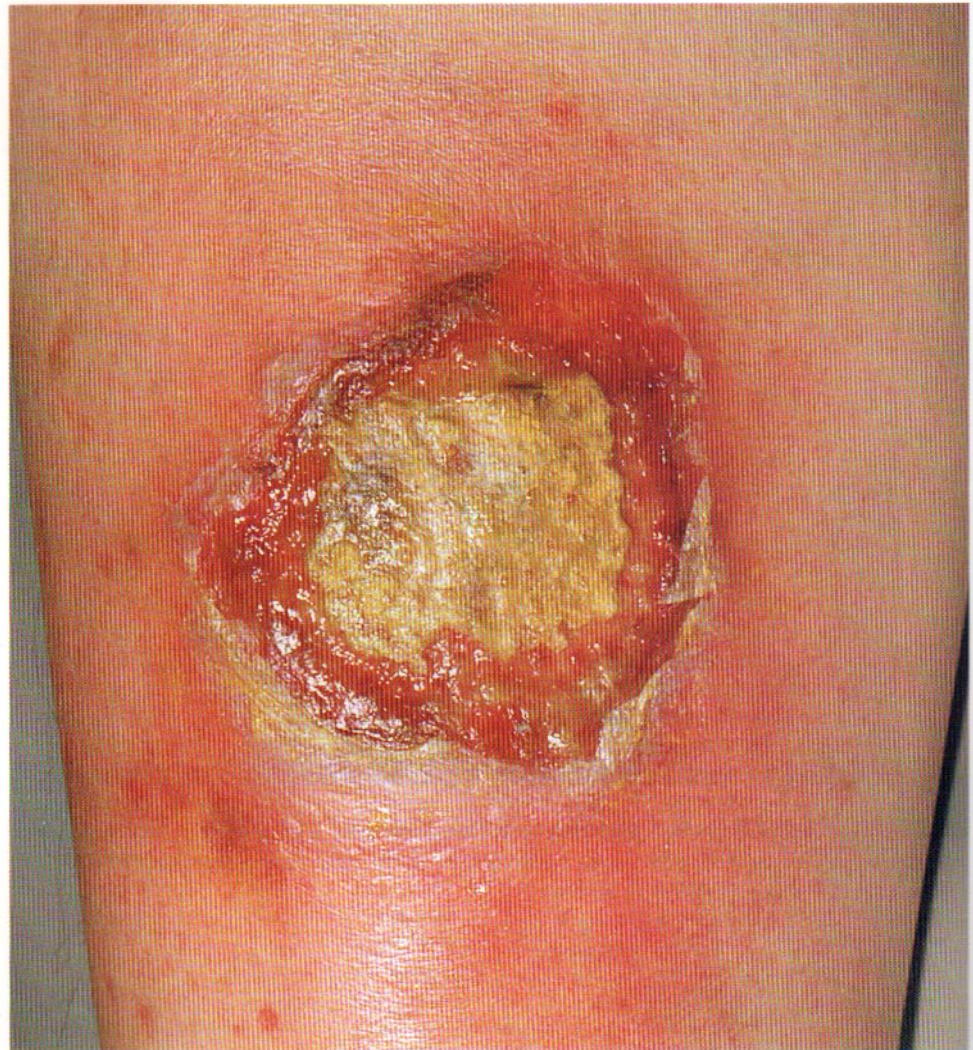
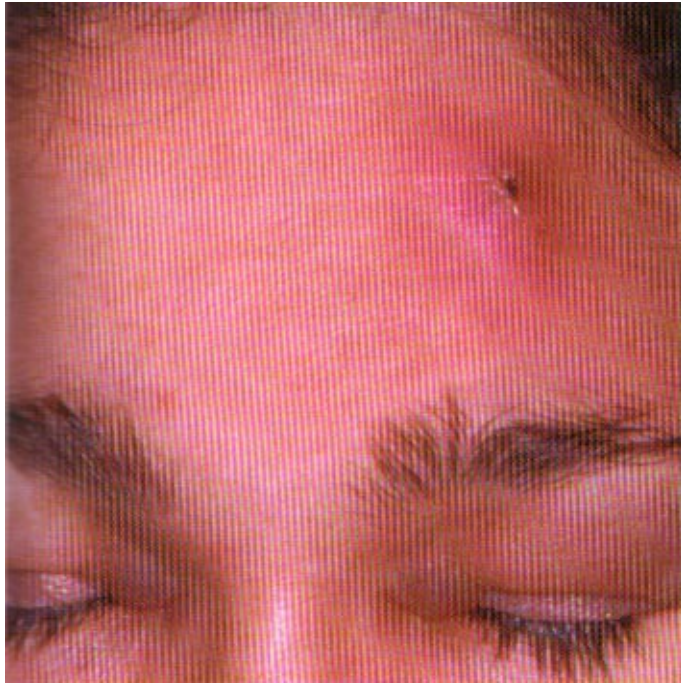
FIGURE 22-14 Ecthyma: *S. aureus* *A large, circumscribed chronic ulcer with surrounding erythema in the pretibial region.*

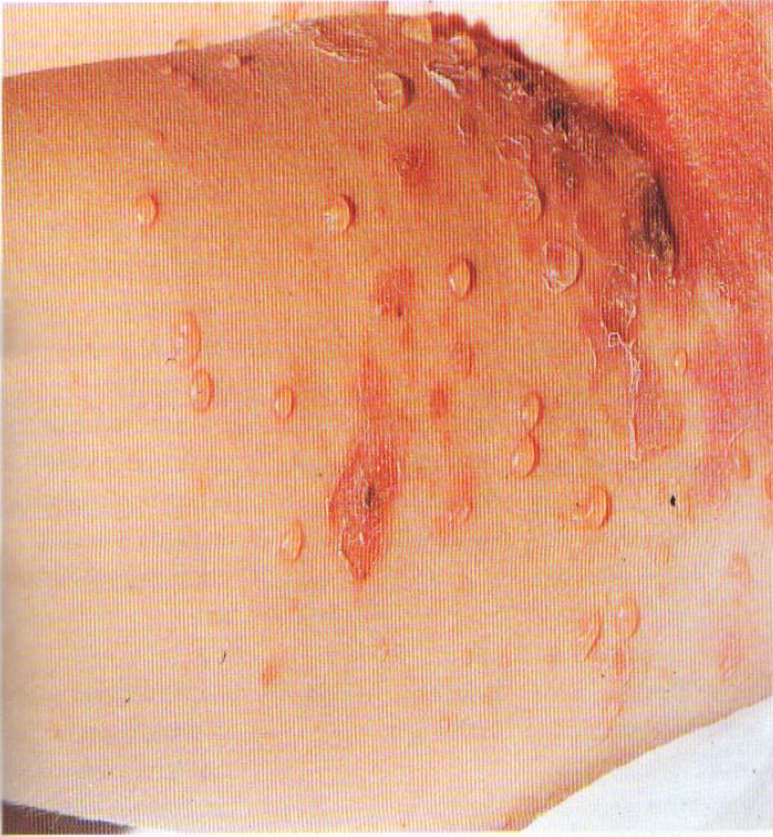

FIGURE 22-12 Bullous impetigo: *S. aureus* Scattered, discrete, intact thin-walled blisters on the thigh of a child; lesions in the groin have ruptured, resulting in superficial erosions.

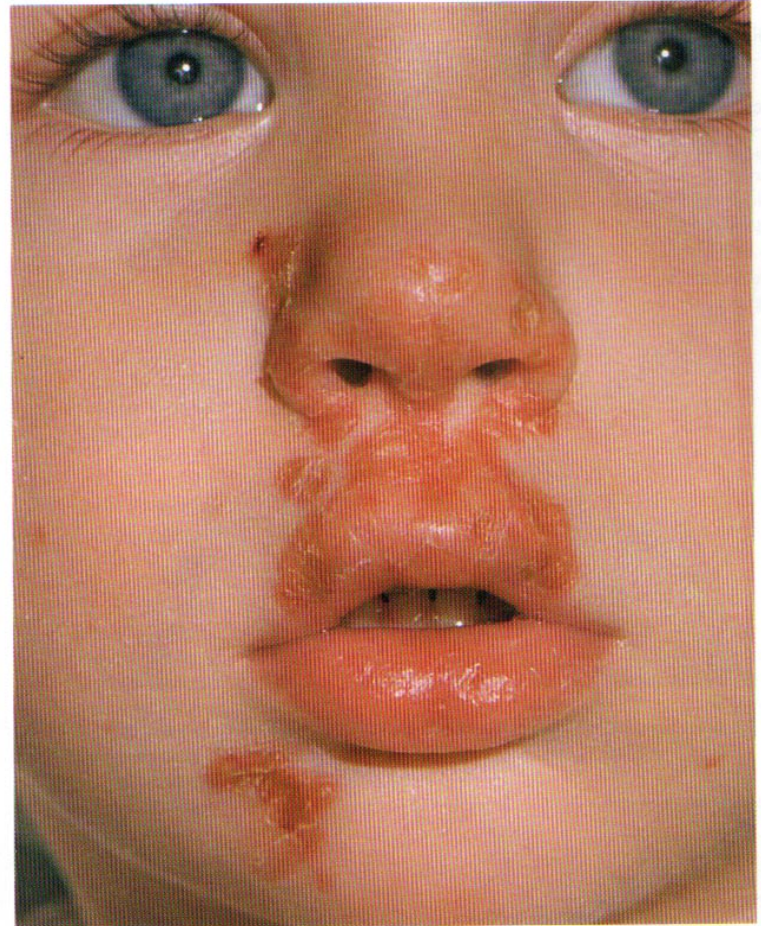


FIGURE 22-10 Impetigo: *S. aureus* Crusted erythematous erosions becoming confluent on the nose, cheek, lips, and chin in a child with nasal carriage of *S. aureus* and mild facial eczema.

Terima **kasih**