

# TurnitinTheGlasgowOutcomeScaleExtendedPediatric

*by Robert Sinurat*

---

**Submission date:** 12-Jul-2021 07:05PM (UTC+0700)

**Submission ID:** 1618682957

**File name:** TheGlasgowOutcomeScale.pdf (117.56K)

**Word count:** 3295

**Character count:** 17023

# The Glasgow Outcome Scale-Extended Pediatric Scores of Intracranial Bleeding Patients with Acquired Prothrombin Complex Deficiency Post Craniotomy and Duraplasty

Robert Sinurat

Surgery Department, Medical Faculty of Universitas Kristen Indonesia, Jakarta, Indonesia

## Keywords

GOS-ePed score · Intracranial bleeding · Craniotomy · Duraplasty · Acquired prothrombin complex deficiency

## Abstract

**Introduction:** Surgical evacuation of intracranial bleeding in pediatric patients due to acquired prothrombin complex deficiency (APCD) is a life-saving surgery when conservative treatment insufficient and impending brain herniation. This study aimed to evaluate the Glasgow outcome scale-extended pediatric (GOS-ePed) score of the pediatric intracranial bleeding patients with APCD after craniotomy and duraplasty. **Method:** This was a retrospective study in the last 5 years of our experience. All of the pediatric patients with intracranial bleeding due to APCD who needed surgery were investigated. The data were collected from medical records after their parents have given their written informed concern and approved by the Ethics Review Committee, Faculty of Medicine, Universitas Kristen Indonesia. The inclusion criteria were patients who operated on by craniotomy and duraplasty. The patient with a second disease was excluded. Blood tests include hemoglobin, prothrombin time, activated prothrombin time, and platelets were investigated before and after intravenous vitamin K injection, transfusion packed red cells (PRCs), and fresh frozen plasma (FFP) administration.

The Glasgow coma scale (GCS) pre- and postoperatively was evaluated using a modified GCS for infants and children. The outcome was evaluated by the GOS-ePed score. All data were analyzed with the normality test and paired *t* test. **Results:** There were 125 patients age between 37 and 60 days, and all patients did not get vitamin K prophylaxis after birth. The blood tests of all patients revealed anemia, prothrombin, and activated prothrombin time increased, but platelets were normal. All these values returned to normal after vitamin K injection, transfusion of PRCs, and FFP. The paired *t* tests were  $p < 0.05$ . The GCS of all patients before surgery was 8 or below. After surgery, the GCS of 4 patients was increased become 12 and 15. One patient did not change significantly. The GOS-ePed score showed 4 patients (80%) had upper or lower good recovery, and 1 patient (20%) was in a vegetative state. **Conclusions:** The GOS-ePed score of the pediatric intracranial bleeding with APCD after craniotomy and duraplasty was mostly in upper or lower good recovery.

© 2020 S. Karger AG, Basel

## Introduction

Pediatric intracranial bleeding related to acquired prothrombin complex deficiency (APCD) can be very fatal, and deficiency of vitamin K is part of the causes. Coagula-

**Table 1.** Hemoglobin and hematocrit

Patient/age	Before transfusion, g/dL	After transfusion, g/dL	Sig. (2-tailed)
1. Boy/37 days	4.1 (12.0)	12.4 (37.2)	0.007
2. Boy/51 days	8.5 (25.0)	11.7 (34.7)	
3. Boy/46 days	7.2 (21.0)	10.5 (31.0)	
4. Boy/43 days	6.5 (19.2)	10.7 (31.5)	
5. Boy/60 days	3.6 (11.5)	10.2 (30.5)	

tion factors II, VII, IX, and X depends on vitamin K in clothing cascade, and neonates can suffer from vitamin K deficiency because of low-level concentration transferred from the placenta or breast milk [1, 2].

Intracranial bleeding of deficiency vitamin K is classified as early (24 h after birth), classical (2–14 days), and late (2 weeks–6 months). The incidence rate was 0.25–1.7% birth rate for early onset and 4.4–7.2 per 100,000 infants [3]. Intramuscular administrations of 1 mg vitamin K were suggested as prophylaxis after birth [4, 5], but not all parents agree with the procedures [3, 6, 7].

The treatment of this intracranial bleeding is conservative, but some cases needed surgical evacuation when conservative management insufficient and brain herniation sign exists [8, 9]. Preoperative management and surgical techniques are important factors for the patient's outcome. During craniotomy procedures, sometimes the brain was very tight and severe edema. It was difficult to close the dura. Decompressive craniectomy and duraplasty are an option for making more space to the brain and the outcome improve [8–11]. But there is no report yet about the craniotomy and duraplasty for these cases. This study aimed to evaluate the outcomes of the intracranial bleeding patient with APCD after craniotomy and duraplasty.

### Material and Methods

This was a retrospective study in the last 5 years of experience. The data were collected from medical records after their parents have given their written informed concern and approved by the Ethics Review Committee, Faculty of Medicine, Universitas Kristen Indonesia.

All pediatric patients with intracranial bleeding due to APCD who needed surgical evacuation and meet the criteria were studied. The inclusion criteria were the patient who operated on by craniotomy and duraplasty due to the brain swelling. Patients also visited neurosurgery outpatient clinic until 6 months postoperative or more. Meanwhile, the patient with the second disease was excluded.

The GOS-ePed Scores of Pediatric Intracranial Bleeding with APCD

**Table 2.** Platelet

Patient	Cell/mL
1	585,000
2	322,000
3	441,000
4	253,000
5	605,000

We analyze the history of vitamin K prophylaxis after birth, the blood test results, the Glasgow coma scale (GCS) before and after surgery, and the outcomes of patients 7 months after surgery. Blood tests include hemoglobin, platelets, prothrombin time (PT), and activated prothrombin time (aPTT). The modified GCS for infants and children was used to assess pre- and postoperative GCS. It starts from the worst (3) until the best (15). Meanwhile, the outcomes were examined by the Glasgow outcome scale-extended pediatric score (GOS-ePed) 6 months after surgery. GOS-ePed classified as (1) upper good recovery, (2) lower good recovery, (3) upper moderate disability, (4) lower moderate disability, (5) upper severe disability, (6) lower severe disability, (7) vegetative state, and (8) death [12]. All data were tabulated and analyzed with the normality test and paired *t* test. A *p* value <0.05 was considered as statistically significant.

### Results

In the last 5 years, there were 5 cases of intracranial bleeding with APCD can meet the criteria of this study. None of them had vitamin K injections after birth. The patient's age ranged from 37 to 60 days. All patients had hemoglobin below normal and managed by packed red cells (PRCs) transfusion dose (10 g/dL – Hb) × Body-weight × 4. After the transfusion, hemoglobin was normal, as showing in Table 1. The paired *t* test of hemoglobin results before and after PRC transfusion was significant.

Table 2 showed platelet concentration was normal in all patients, while PT and aPTT increased. Vitamin K intravein injection 1 mg and 10 mL/kg body weight/day of fresh frozen plasma (FFP) transfusion have improved the PTT and aPTT. Paired *t* test results showed the difference (Tables 3, 4).

The brain CT scans of all patients showed subdural hemorrhagic, intracerebral hemorrhagic, or combination. The location mostly in the temporal and parietal regions with midline shifts >5 mm as shown in Table 5 and Figure 1.

Pediatr Neurosurg 2020;55:254–258  
DOI: 10.1159/000511020

255

**Table 3.** Prothrombin time

Patient	Before transfusion, s	After transfusion, s	Sig. (2-tailed)
1	53.0	13.7	0.008
2	61.4	14.3	
3	100.9	23.1	
4	98.5	22.3	
5	35.9	13.4	

**Table 4.** Activated partial thromboplastin time

Patient	Before transfusion, s	After transfusion, s	Sig. (2-tailed)
1	74.6	37.7	0.032
2	40.6	29.3	
3	123.0	40.8	
4	111.5	39.7	
5	57.5	36.0	

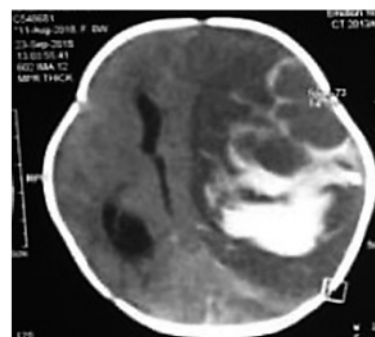
**Table 5.** Brain CT scan and surgery procedures

Patient	Brain CT scan	Surgery
1	ICH left temporoparietal	Craniotomy and duraplasty
2	SDH right temporoparietal	Craniotomy and duraplasty
3	SDH + ICH right temporoparietal	Craniotomy and duraplasty
4	SDH bitemporal and occipital	Craniotomy and duraplasty
5	ICH left temporoparietal	Craniotomy and duraplasty

**Table 6.** GCS and GOS-ePed score

Patient	GCS (preoperative)	GCS (postoperative)	GOS-e Peds
1	5	12	2
2	7	13	1
3	8	15	1
4	4	5	7
5	6	13	1

GCS, Glasgow coma scale; GOS-ePed, Glasgow outcome scale-extended pediatric.

**Fig. 1.** Brain CT scan showed intracerebral hemorrhage with midline shift.

Preoperative GCS of all patients were between 4 and 8. One week postoperative, 4 of 5 patients were improved become 12 and 15. But the patient number 4 was not changed significantly. Six months after surgery, the GOS-ePed score of 4 patients (80%) was a good recovery, and the fourth case did not improve significantly. It was a vegetative state, and his pupil was dilated and not reactive. No patient has died (Table 6).

### Discussion

This study revealed 5 cases of intracranial hemorrhage due to APCD in 5 years. The age of all patients was more than 37 days, while Zidan and Abdel-Hady [10] had an

average age of 20–25 days. The condition may be caused by a lack of knowledge and understanding of the patient's parents about the symptoms, then delayed coming to the hospital. All the patients were in a coma, and there was no history of vitamin K prophylaxis at birth. A previous systematic review revealed low-quality evidence for routine intramuscular 1 mg of vitamin K at birth, but still appropriate to administer it because of the high risk of mortality and morbidity [13].

The blood test results of all patients showed anemia and another previous study [14] revealed the same result. PRC transfusion can improve hemoglobin immediately

to the normal range. PTT and aPTT measures were increased in all patients, but the platelets were normal. It was matched with the vitamin K deficiency in neonates while they do not use antiplatelet drugs. All of these patients did not obtain vitamin K prophylaxis newborns. Schulte et al. [7] have reported in their study of intracranial bleeding pediatric patients due to vitamin K deficiency because the patients' parents refused to vitamin K prophylaxis newborn for their babies.

FFP transfusion and vitamin K intravenous administration can change the value of PTT and aPTT back to normal. And the patients can be operated on. Craniotomy procedures were intended to evacuate blood clots in the subdural space and intracerebral hemorrhage. Before the bone flap was fixed, duraplasty was performed using the pericranium layer. It was very useful for increasing intracranial space with duraplasty because it can reduce intracranial pressure [8].

The results of this study revealed GOS-ePed score of 80% of patients was between upper and lower good recovery, without death. It was better than other previous studies have reported [6, 10, 14, 15]. The mortality rate was from 12 to 25%. Zidan and Abdel-Hady [10] have reported 6 patients out of 32 patients (18.8%) died after the evacuation of intracranial hemorrhage due to vitamin K deficiency. They had evacuated the bleeding by free or osteoblastic bone flap. Dewi et al. [16] also have reported that craniotomy procedures were needed for moderate and severe intracranial bleeding due to APCD. Their operative outcomes were good, but they did not explain about the severity of the patient's brain edema during surgery.

In this study, there was 1 patient in a vegetative state. It was possible because the brain damage was very severe because of prolonging high-intracranial pressure before the decompression procedure has done. Patient's GCS before surgery was the lowest and although decompression surgery has performed, the GCS did not increase significantly. Postoperative GCS remained below 8, and the pupils were dilated and not reactive. The brain damage is permanent [10].

The early surgery versus initial-conservative treatments in patients with spontaneous supratentorial lobar intracerebral hematomas (STICH II) randomized trial obtained an unfavorable outcome 59% of the surgical patients versus 62% in the patients' initial-conservative group. There was not any difference in morbidity and mortality between the 2 groups [17]. However, the study had a weak point: one-quarter of the initial-conservative patients crossed over into surgery. Without crossed-over

patients, it is possible mortality, and the unfavorable outcomes in the initial-conservative groups will be higher [18].

Benefits of supratentorial hematoma evacuation in adult patients' trial appear to be limited. But in children who have less compliance and brain atrophy, the procedures were needed for reduction of mass effect and prevent brain herniation. Decompressive craniotomy is effective and might be potentially for saving life [19].

At present, minimally invasive surgery is highly developed. The evacuation of supratentorial intracerebral hematoma rate was greater than 90% [20, 21]. However, minimally invasive surgery with thrombolysis in intracerebral hemorrhage (MISTIE III) trial has stated MISTIE did not improve the long-term outcomes [22]. This study and also the study of Zidan and Abdel-Hady [10] showed that most of the bleeding was an acute subdural hemorrhage. Minimal invasive endoscopy techniques in acute subdural hemorrhage have been reported to be effective enough to evacuate bleeding in selective cases only. It must be ensured that the evacuation of the bleeding can reduce intracranial pressure [23, 24].

## Conclusion

Intracranial bleeding due to vitamin K deficiency must be considered when neonates suffer from convulsion or decreased consciousness without fever, especially babies who do not get vitamin K injection after birth. Craniotomy and duraplasty procedures can improve the GOS-ePed score of pediatric intracranial bleeding patients due to APCD and with severe brain edema. However, if the GCS before and after surgery were very low, the outcome score will be poor.

## Statement of Ethics

This study was approved by the Ethics Review Committee, Faculty of Medicine, Universitas Kristen Indonesia. Number: 30/Etik Penelitian/FKUKI/2019.

## Conflict of Interest Statement

No potential conflict of interest relevant to this article.

## Funding Sources

The authors did not receive any funding.

- 1 Shearer MJ. Vitamin K metabolism and nutrition. *Blood Rev.* 1992;6(2):92–104.
- 2 Van Hasselt PM, de Koning TJ, Kvist N, De Vries E, Lundin CR, Berger R, et al. Prevention of vitamin K deficiency bleeding in breastfed infants: lessons from Dutch and Danish biliary atresia registries. *Pediatrics.* 2008;121(4):e857–63.
- 3 Warren M, Miller A, Traylor J, Sidonio R, Morad A, Goodman A, et al. Notes from the field: late vitamin K deficiency bleeding in infants whose parents declined vitamin K prophylaxis: Tennessee, 2013. *MMWR Morb Mortal Wkly Rep.* 2013;62(45):901–2.
- 4 Mihatsch WA, Braegger C, Bronsky J, Campoy C, Domellöf M, Fewtrell M, et al. Prevention of vitamin K deficiency bleeding in newborn infants: a position paper by the ESPGAN committee on nutrition. *J Pediatr Gastroenterol Nutr.* 2016;63(1):123–9.
- 5 Ardell S, Offringa M, Ovelman C, Soll R. Prophylactic vitamin K for the prevention of vitamin K deficiency bleeding in preterm neonates. *Cochrane Database Syst Rev.* 2018;2(2):CD008342.
- 6 Zurynski Y, Ridley G, Jalaludin B, Elliot E. 21 years of surveillance for vitamin K deficiency bleeding in infants: policy changes in Australia and international comparisons. *Arch Dis Child.* 2018;103:A200–2.
- 7 Schulte R, Jordan LC, Morad A, Naftel RP, Wellons JC, Sidonio R. Rise in late onset vitamin K deficiency bleeding in young infants because of omission or refusal of prophylaxis at birth. *Pediatr Neurol.* 2014;50(6):564–8.
- 8 Gopakumar H, Sivji R, Rajiv PK. Vitamin K deficiency bleeding presenting as impending brain herniation. *J Pediatr Neurosci.* 2010;5(1):55–8.
- 9 Williams V, Jayashree M, Bansal A, Baranwal A, Nallasamy K, Singhi SC, et al. Spontaneous intracranial haemorrhage in children-intensive care needs and predictors of in-hospital mortality: a 10-year single-center experience. *Childs Nerv Syst.* 2019;35:1371–9.
- 10 Zidan AS, Abdel-Hady H. Surgical evacuation of neonatal intracranial hemorrhage due to vitamin K deficiency bleeding. *J Neurosurg Pediatr.* 2011;7(3):295–9.
- 11 Sethuraman JK, Ashok AK. Impact of the extent of craniectomy and duraplasty on post-operative outcome following decompressive craniectomy for traumatic brain injury. *Int J Dev Res.* 2017;7(12):17906–11.
- 12 Beers SR, Wisniewski SR, Garcia-Filion P, Tian Y, Hahner T, Berger RP, et al. Validity of a pediatric version of the glasgow outcome scale-extended. *J Neurotrauma.* 2012;29(6):1126–39.
- 13 Sankar MJ, Chandrasekaran A, Kumar P, Thukral A, Agarwal R, Paul VK. Vitamin K prophylaxis for prevention of vitamin K deficiency bleeding: a systematic review. *J Perinatol.* 2016;36(Suppl 1):S29–35.
- 14 Adhikari S, Gauchan E, Malla T, Sathian B, Rao KS. Intracranial hemorrhage caused by vitamin K deficiency beyond neonatal period. *J Nepal Paediatr Soc.* 2017;37(1):104–7.
- 15 Ozdemir MA, Karakukcu M, Per H, Unal E. Late vitamin K deficiency bleeding: experience from 120 patients. *Childs Nerv Syst.* 2012;28:247–51.
- 16 Dewi LP, Nurfitri E, Evodia E, Romli MT. Good outcomes in operative management of acquired prothrombin complex deficiency: a serial case report. *Paediatr Indones.* 2011;51(5):298–302.
- 17 Pendelow AD, Gregson BA, Rowan EN, Murray GD, Gholkar A, Mitchell PM, et al. Early surgery versus initial conservative treatment in patients with spontaneous supratentorial lobar intracerebral haematomas (STICH II): a randomised trial. *Lancet.* 2013;382(9890):397–408.
- 18 De Oliveira Manoel AL. Surgery for spontaneous intracerebral hemorrhage. *Crit Care.* 2020;24(1):45.
- 19 Ferrero DM, Fullerton HJ, Bernard TJ, Billingham L, Daniels SR, DeBaun MR, et al. Management of stroke in neonates and children: a scientific statement from the American heart association/American stroke association. *Stroke.* 2019;50(3):e51–96.
- 20 Campbell III JC, Greenberg SM, Anderson CS, Becker K, Bendok BR, Cushman M, et al. Guidelines for the management of spontaneous intracerebral hemorrhage. *Stroke.* 2015;46:2032–60.
- 21 Shengli Q, Tao L, Guanghui C, Kun W, Tingsheng Z. Treatment of intracranial hemorrhage with neuroendoscopy guided by body surface projection. *Medicine.* 2019;98(19):e15503.
- 22 Ganley DF, Thompson RE, Rosenblum M, Yenokyan G, Lane K, McBee N, et al. Minimally invasive surgery with thrombolysis in intracerebral haemorrhage evacuation (MISTIE III): a randomised, controlled, open-label phase3 trial with blinded endpoint. *Lancet.* 2019;393(10175):1021–32.
- 23 Fortuni E, Khattar NK, John K, Bak E, Adams SW, Meyer KS, et al. Minimally invasive endoscopy versus craniotomy for acute subdural hematomas: a retrospective matched cohort study. *Neurosurgery.* 2019;66(Suppl 1).
- 24 Haruya J, Tamura S, Hasegawa R, Saito A, Nishimaki K, Fujii Y. Endoscopic hematoma evacuation following emergent burr hole surgery for acute subdural hematoma in critical conditions: technical note. *Interdiscip Neurosurg.* 2018;12:48–51.

# TurnitinTheGlasgowOutcomeScaleExtendedPediatric

## ORIGINALITY REPORT

10%

SIMILARITY INDEX

7%

INTERNET SOURCES

10%

PUBLICATIONS

5%

STUDENT PAPERS

## PRIMARY SOURCES

1	<a href="http://thejns.org">thejns.org</a> Internet Source	2%
2	Junwei Ren, Xing Wu, Jiongwei Huang, Xudong Cao, Qiang Yuan, Dalong Zhang, Zhuoying Du, Ping Zhong, Jin Hu. "Intracranial Pressure Monitoring-Aided Management Associated with Favorable Outcomes in Patients with Hypertension-Related Spontaneous Intracerebral Hemorrhage", Translational Stroke Research, 2020 Publication	1%
3	<a href="http://www.eshre.eu">www.eshre.eu</a> Internet Source	1%
4	<a href="http://e-sciencecentral.org">e-sciencecentral.org</a> Internet Source	1%
5	Anna-Lisa Sorg, Mathias Klemme, Rüdiger von Kries, Ursula Felderhoff-Müser, Andreas W. Flemmer, Lucia Gerstl, Mark Dzierko. "Clinical Diversity of Cerebral Sinovenous Thrombosis and Arterial Ischaemic Stroke in the Neonate: A Surveillance Study", Neonatology, 2021	1%

6

Radhian Amandito, Rinawati Rohsiswatmo, Michelle Halim, Vanessa Tirtatjahja, Amarila Malik. "SLCO1B1 c.388A > G variant incidence and the severity of hyperbilirubinemia in Indonesian neonates", BMC Pediatrics, 2019

Publication

---

7

"Pediatric Hepatology and Liver Transplantation", Springer Science and Business Media LLC, 2019

Publication

---

8

Sankar, M J, A Chandrasekaran, P Kumar, A Thukral, R Agarwal, and V K Paul. "Vitamin K prophylaxis for prevention of vitamin K deficiency bleeding: a systematic review", Journal of Perinatology, 2016.

Publication

---

9

[www.scielo.br](http://www.scielo.br)

Internet Source

---

10

[www.thieme-connect.com](http://www.thieme-connect.com)

Internet Source

---

11

Airton Leonardo de Oliveira Manoel. "Surgery for spontaneous intracerebral hemorrhage", Critical Care, 2020

Publication

---

12

[mafiadoc.com](http://mafiadoc.com)

Internet Source

---

1 %

1 %

1 %

1 %

1 %

1 %

1 %



---

Exclude quotes      On

Exclude matches      < 1%

Exclude bibliography      On