

Management of Traumatic Hyphema with Anterior Chamber Maintainer

by Gilbert W S Simanjuntak

Submission date: 23-Jul-2018 03:57PM (UTC+0700)

Submission ID: 984586318

File name: 5._Seminars_in_Ophthalmol_2012-Hyphema_with_ACM.pdf (601.69K)

Word count: 1575

Character count: 8103

ORIGINAL ARTICLE

Management of Traumatic Hyphema with Anterior Chamber Maintainer

Gilbert W.S. Simanjuntak^{1,2}, Jusuf Wijaya^{1,2}, and Helario Hasibuan^{1,2}

¹Department of Ophthalmology Faculty of Medicine, Christian University of Indonesia, Jakarta, Indonesia and
²Cikini Eye Institute/Cikini CCI Hospital, Jakarta, Indonesia

ABSTRACT

Background: To describe the technique for the removal of bulky fibrin in persistent traumatic full hyphema by using anterior chamber maintainer (ACM).

Methods: The ACM was used to form and maintain the anterior chamber, and to flush out the clotted blood. The ACM cannula was inserted at the 6 o'clock position, and then a 2-mm-width contra lateral limbal incision was made. Slight pressure applied at the posterior lip of the incision facilitated the evacuation of the clot from the anterior chamber. Visible adherence of the clot was separated using the Sinsky hook, and firm fibrosis between fibrin and intraocular structure was cut by Vannas scissor.

Results: All liquified blood was removed through corneal incision. Any clot caught at the incision was removed by cutting the clot into smaller fragments with a Vannas scissor.

Conclusion: ACM is a safer and affordable alternative compared to Simcoe's cannula or vitrectomy in the removal of persistent traumatic hyphema.

Keywords: anterior chamber maintainer, hyphema, eye injury, surgical technique, developing country

INTRODUCTION

Hyphema, either caused by trauma or the result of other etiology, can lead to increased intra ocular pressure (IOP). "Eight ball hyphema" could lead to permanent corneal staining and permanent visual loss due to damage of the optic nerve. To date, the surgical technique recommended for the removal of the blood clot from the anterior chamber (AC) has been the use of vitrectomy¹ or Simcoe's cannula. In this article, we would like to introduce a simple and affordable technique using an anterior chamber maintainer (ACM) that is able to achieve excellent results after surgery.

SURGICAL TECHNIQUE

A 20 G beveled down needle was penetrated parallel to the limbus at the six o'clock position to insert the ACM. Once the ACM was secured into position, the infusion line was then opened. The infusion bottle was

at a height of about 50–60 cm above the patient's eye. A contra lateral 2 mm incision port was created at the 12 o'clock position. Gentle pressure at the posterior incision lip was applied to evacuate the mixture of aqueous humor and lysed blood. This in turn facilitates the visualization of the actual blood clot in anterior chamber. Any strong adherence due to fibrosis of the clot/dense fibrin either to the iris or the cornea could then be separated by gentle manipulation with a Sinsky hook. Complete separation of the clot or dense fibrin is marked by the observance of rotation of the whole clot in the anterior chamber due to fluid flow from the ACM. The clot was then drawn to the superior incision (Figure 1). Utilizing Lim's forceps, the clot was gently pulled out of the anterior chamber and dissected with the Vannas scissors (Figure 2). In cases where more attachment is encountered, a long-bladed Vannas scissors should be introduced into the anterior chamber to cut these attachments free without causing any damage to the surrounding structures, as the ACM maintains the depth of the AC during the

The authors thank Romanti Kardono, M.D. (Jakarta, Indonesia), and Avinash Pathengay, M.D., FRCS (LV Prasad Eye Institute, Hyderabad, India), for editing the article before it was submitted.

Received 15 February 2011; revised 16 March 2011; accepted 21 July 2011

Correspondence: Gilbert W.S. Simanjuntak, M.D., Department of Ophthalmology Faculty of Medicine, Christian University of Indonesia, Jalan PS Sutoyo, Cawang, Jakarta, Indonesia. E-mail: retinaid@yahoo.com

whole procedure. If the clot doesn't show any further willingness to exit, it can be pushed back into the anterior chamber and rotated so that a smaller portion of the clot could once again be engaged at the incision. Once the whole clot has evacuated from the anterior chamber, the infusion line would be stopped and the AC then was reformed with BSS and air. The ACM could then be disengaged by rotating and pulling it backwards gently.

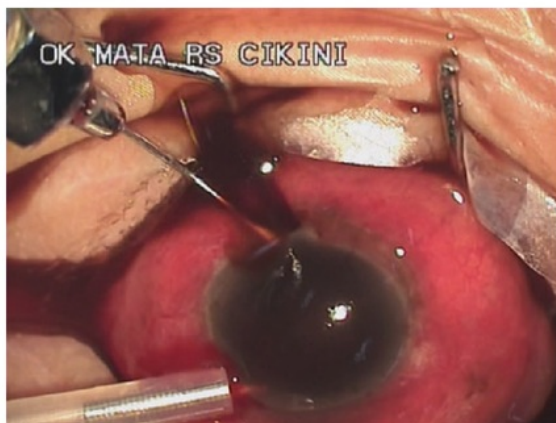


FIGURE 1 Gentle pressure applied at the incision lip to evacuate the blood-aqueous humor mixture will facilitate viewing of the fibrosis/clothing that has occurred in the anterior chamber.

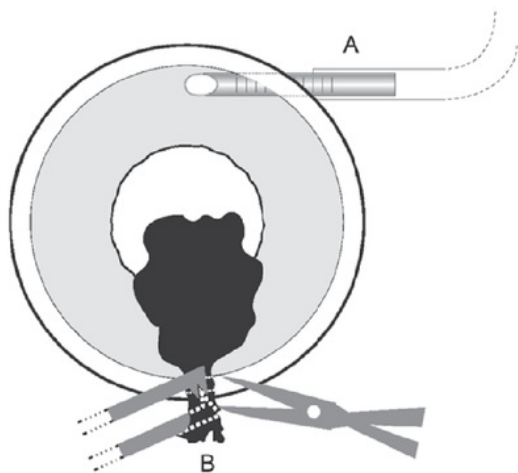


FIGURE 2 [A] The ACM inserted at six o'clock position. Raising the bottle height 50–60 cm above the patient's eye will create positive pressure inside the eye. Gentle pressure at the posterior contra lateral incision lip was applied to evacuate the mixture of aqueous humor and lysed blood. [B] Any clot caught inside was gently pulled out of the anterior chamber and dissected with the Vannas scissor.

Gentamicine and dexamethasone were then injected subconjunctivally. After the operation, the patient was given eye drops of 1% gentamicine, dexamethasone and 0.5 % timolol during the next four weeks.

DISCUSSION

Hyphema in children due to accidental shooting with toy guns occurs quite frequently in our city.² Although it rarely occurs, hyphema with associated fibrin can progress to IOP increases and subsequent blood staining of cornea, rendering surgical intervention. In our technique, draining the hyphema using the ACM achieved the same results as when drained through Simcoe's cannula or using the vitrector.¹

The procedure was carried out on three cases of pediatric persistent full hyphema under general anesthesia (by GWSS) (Table 1). All cases were due to accidents with toy guns. In all cases the full hyphema persisted for more than two days and resulted in secondary glaucoma. The decrease in visual acuity was all due to the blood clot blocking the pupil. All cases improved once the clot had been successfully removed (include visual acuity and IOP before and after the procedure during the last visit).

Purchasing the vitrectomy machine (the cheapest cost in our country is US \$ 45,000) for the management of these cases is sometimes unaffordable in developing countries and appears excessive. Both Simcoe's cannula and vitrector have relatively small "mouths" that create problems in removing bulky and springy fibrin in the AC. The ACM (the cost is US \$ 10) has been used in cataract surgery, either in manual small incision cataract surgery or in phacoemulsification.³⁻⁶

There is limitation of Simcoe's cannula and vitrector in this procedure. Both Simcoe's cannula and vitrector have relatively small "mouths" so that they create problems in removing bulky and springy fibrin in the AC. In addition, the vitrectomy machine is costly and seems excessive. For fresh and/or liquefied hyphema, it can be aspirated. However, for bulky and springy tissue it was our experience that it is difficult to remove them in the vitreous cavity when doing a vitrectomy, and more difficult when the space is narrower, such as in AC in comparison to the vitreous cavity.

Further advantages of the ACM are the exclusion of the use of viscoelastics in these pediatric cases, as any remaining viscoelastics could result in elevated IOP, which is usually quite severe since this occurs in an inflamed anterior chamber. The 2 mm superior limbal

TABLE 1 Demography of patients, pre- and post-operatively

Patient	Age (years)	Duration (hours)	Preoperative VA	Preoperative IOP (mmHg)	Postoperative VA 1 week	Postoperative IOP (mmHg)	Follow-up (months)
1	10	>48	LP	42.1	6/6	13.1	3
2	11	>48	LP	49.8	6/6	10.9	2
3	13	>48	LP	42.1	6/6	10.9	3

parallel incision and perpendicular inferior entry port will induce very minimal iatrogenic astigmatism.

In conclusion, the use of the ACM for the removal of persistent traumatic hyphema is a viable, safe, and more economic method with results comparable to Simcoe's cannula and vitrectomy.

Declaration of interest: The authors report no conflicts of interest. The authors alone are responsible for the content and writing of the paper.

REFERENCES

1. Boyd BF. Management of ocular trauma, Part III. *Highlights of Ophthalmology* 1996;24(1):3–6.
2. Simanjuntak GWS, Aldian D, Artini W, et al. *Traumatic hyphema in school age children due to toys gun*. Indonesia Annual Meeting 1997, Jakarta. Poster.
3. Blumenthal M. Manual ECCE, the present state of the art. *Klin Monatsbl Augenheilkd.* 1994 Nov;205(5):266–70.
4. Chawla HB, Adams AD. Use of the anterior chamber maintainer in anterior segment surgery. *J Cataract Refract Surg.* 1996 Mar;22(2):172–7.
5. Abdoudi S, Brazitikos PD, Papadopoulos NT, Derekliis D, Symeon L, Stangos N. Posterior capsule rupture and vitreous loss during phacoemulsification with or without the use of an anterior chamber maintainer. *J Cataract Refract Surg.* 2004 Feb;30(2):449–52.
6. Blumenthal M, Assia EI, Chen V, Avni I. Using an anterior chamber maintainer to control intraocular pressure during phacoemulsification. *J Cataract Refract Surg.* 1994 Jan;20(1):93–6.

Management of Traumatic Hyphema with Anterior Chamber Maintainer

ORIGINALITY REPORT

15%

SIMILARITY INDEX

10%

INTERNET SOURCES

13%

PUBLICATIONS

3%

STUDENT PAPERS

PRIMARY SOURCES

1

www.ofthalmoloji.org

Internet Source

2%

2

www.researchgate.net

Internet Source

2%

3

www.jove.com

Internet Source

2%

4

M. Baykara, C. Özakin, M. doğru, H. Ertürk, Y. Heper, H. Özçetin. "The Effect of Anterior Chamber Maintainer on Anterior Chamber Contamination", European Journal of Ophthalmology, 2018

Publication

1%

5

Gilbert WS Simanjuntak, Golda AM Simanjuntak, Reinne Natali Christine. "Macular hole surgery under retrobulbar local anesthesia increases visual acuity", Universa Medicina, 2017

Publication

1%

6

Internet Source

1%

7

keratoconuscanada.org

Internet Source

1%

8

Bayramlar, H.. "Manual tunnel incision extracapsular cataract extraction using the sandwich technique", Journal of Cataract & Refractive Surgery, 199903

Publication

1%

9

Zong-M Song. "A New Approach for Active Removal of 5,000 Centistokes Silicone Oil Through 23-Gauge Cannula :", Retina, 09/2010

Publication

1%

10

Tao Yu. "Use of an anterior chamber maintainer in the surgical management of traumatic hyphaemas", Clinical & Experimental Ophthalmology, 4/2008

Publication

<1%

11

Isaak Schipper. "Implantation of a Staar silicone intraocular lens with the anterior chamber maintainer", Journal of Cataract & Refractive Surgery, 1996

Publication

<1%

12

Cohen, Adam B., and Simmons Lessell. "Angiogenesis and Pituitary Tumors", Seminars in Ophthalmology, 2009.

Publication

<1%

13 Wang, Yuhong, and Li Nie. "Use of the Anterior Chamber Maintainer in Trabeculectomy Following Vitrectomy", Current Eye Research, 2011.

<1%

Publication

14 Guangsheng Chen, Dongmei Wang, Yi Du, Hongbo Huang. "Effect of Continuous Ultrasonic Phacoemulsification with Anterior Chamber Maintainer on Corneal Endothelial Damage in Hard Nuclear Cataract", European Journal of Ophthalmology, 2018

<1%

Publication

Exclude quotes On

Exclude matches Off

Exclude bibliography On