

# CornealUlcerwithIntraocular

*by* Layanan Turniitn

---

**Submission date:** 12-Jun-2025 01:25PM (UTC+0700)

**Submission ID:** 2697454573

**File name:** CornealUlcerwithIntraocular.pdf (404.16K)

**Word count:** 4122

**Character count:** 22726



8

**Journal of Advances in Medicine and Medical Research****Volume 37, Issue 5, Page 267-274, 2025; Article no. JAMMR.135845****ISSN: 2456-8899, NLM ID: 101711724****(Past name: British Journal of Medicine and Medical Research, Past ISSN: 2231-0614, NLM ID: 101570965)**

# Corneal Ulcer with Intraocular Involvement

**Reinne Natali Christine <sup>a\*</sup>**<sup>a</sup> Department of Ophthalmology, Faculty of Medicine, Universitas Kristen Indonesia, Jakarta, Indonesia.

3

**Author's contribution***The sole author designed, analysed, interpreted and prepared the manuscript.***Article Information**DOI: <https://doi.org/10.9734/jammr/2025/v37i55836>**Open Peer Review History:**

This journal follows the Advanced Open Peer Review policy. Identity of the Reviewers, Editor(s) and additional Reviewers, peer review comments, different versions of the manuscript, comments of the editors, etc are available here: <https://pr.sdiarticle5.com/review-history/135845>

**Case Report****Received: 12/03/2025****Accepted: 14/05/2025****Published: 22/05/2025****ABSTRACT**

**Background:** Corneal ulcer is a pathologic corneal condition characterized by suppurative infiltrates with indolent corneal defects and corneal tissue discontinuities that can occur from epithelium to stroma. Corneal ulcers can occur as a result of trauma by a foreign body or a disease that causes the entry of bacteria or fungi into the cornea, causing infection or inflammation.

**Aims:** to report a case of corneal ulcer caused by bacterial infection, and review the patient's management and clinical progress.

**Case presentation:** Two cases of corneal ulcers were presented with different bacterial causes. The first case is a man aged 54 years with a history of trauma on the corneal epithelium, the corneal ulcer is then known to be caused by gram-positive germs. Visual repair and healing without sicatrics were achieved after 1 week of treatment. In the second case, a 52-year-old woman with type 2 diabetes mellitus, a corneal ulcer was caused by a highly virulent gram-negative germ, and corneal perforation was found after 2 weeks. Complications of corneal ulcers can result in blindness, so proper microbiological examination and therapy are very important.

**Conclusion:** Bacterial corneal ulcers are an ophthalmologic emergency requiring prompt

\*Corresponding author: E-mail: [reinne.christine@uki.ac.id](mailto:reinne.christine@uki.ac.id);

**Cite as:** Christine, Reinne Natali. 2025. "Corneal Ulcer With Intraocular Involvement". Journal of Advances in Medicine and Medical Research 37 (5):267-74. <https://doi.org/10.9734/jammr/2025/v37i55836>.

diagnosis and therapy. Early identification of the causative pathogen and administration of appropriate antimicrobial therapy are crucial to prevent permanent corneal damage and visual impairment.

**Keywords:** Bacterial; complications; corneal ulcer.

## 1. INTRODUCTION

Corneal ulcer is an emergency condition that threatens vision. If left untreated, this condition can cause progressive damage with corneal perforation and infection in the surrounding tissue (Weisenthal et al., 2014, Sridhar, 2005). Corneal ulcer scarring is one of the main causes of blindness and decreased vision worldwide. Almost all of these blindness cases can be avoided with early diagnosis and appropriate early management, and by minimizing predisposing factors (Biswell, 2011). One of the main causes of monocular blindness in developing countries is caused by corneal ulcers (Srinivasan et al., 1997). In various countries, valid estimated data for the annual incidence of corneal ulcers is quite difficult to obtain. Existing data show that in America, the incidence rate is 11 cases per 100,000 population per year, while in southern India, it is around 10 times higher, with a figure of 113 cases per 100,000 population per year. Worldwide, an estimated 1.5 million eyes are blind due to corneal ulcers, and the actual number is likely higher (Upadhyay et al., 2001). In Indonesia, according to the 2013 basic health research (Riskesdas) data, the national prevalence of corneal opacity was 5.5%. The high prevalence of corneal opacity in the farmer/fisherman/laborer occupational group may be related to a history of mechanical trauma or work accidents to the eyes, considering that the use of personal protective equipment while working has not been optimally implemented in Indonesia (Kesehatan, 2013).

Risk factors that cause corneal ulcers are contact lens use, trauma, conditions or diseases that damage the surface of the cornea (herpetic keratitis, bullous keratopathy, dry eye, chronic blepharitis, trichiation and entropion, severe eye allergies, corneal anesthesia) and other factors such as immunosuppression, diabetes, and vitamin A deficiency (Kanski, 2007, Schaefer et al., 2001). Corneal ulcers can be classified into several types according to: (1) location (central, paracentral, peripheral), (2) depth (superficial or

deep), (3) necrosis (suppurative or non-suppurative), (4) uveal reaction (with or without hypopyon), (5) etiology (infective, allergic, traumatic, tropical, related to systemic disorders, and idiopathic) (Nema and Nema, 2008, Khurana, 2007). The purpose of writing this scientific paper is to report two cases of corneal ulcers with different bacterial causes and to describe the course of the disease with different prognoses of complications in vision.

## 2. CASE REPORT

### Case 1

A 56-year-old male patient with an address in Jakarta. He came to the eye polyclinic of UKI Hospital on February 23, 2018, with complaints of pain in the left eye and decreased vision for 5 days earlier. The patient previously admitted to being splashed by a small object stuck in the middle of his eye while working as a welder in a workshop, then he cleaned the small object by prying it off using a banknote, following his friend's advice. The next day, the left eye was red, vision was blurry, pain in the area around the eye.

There was no history of previous eye disease, history of wearing glasses was denied, and the patient did not have any systemic diseases (hypertension, diabetes mellitus). In the family history, there was no history of systemic disease, tumors, or malignancies.

The results of the left eye examination showed a visual acuity of 1/60. The eyelids appear edematous, there is corneal injection, the anterior chamber is deep, and there is hypopyon, the pupil is round, the diameter is 3 mm, the direct and indirect light reflexes are positive, the lens is clear, and the intraocular pressure on palpation is normal (N). The movement of the eyeballs is free in all directions. On examination with fluorescein, an epithelial defect was found in the cornea of the left eye.

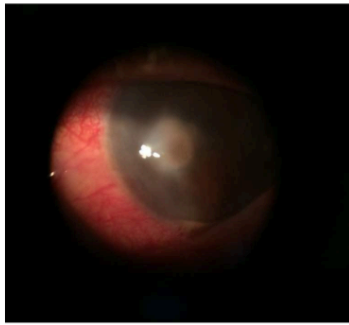


Fig. 1. Anterior segment of the left eye at the first visit

Meanwhile, the examination of the right eye obtained visual acuity of 6/12 pinhole 6/6, and no abnormalities were found in the anterior and posterior segments of the eye. Then, a swab of the left cornea was performed with topical anesthesia for microbiological examination in the form of a Gram examination and sensitivity culture, which was sent to the Microbiology Department of the UKI Medical Faculty. The results of the Gram examination showed gram-positive (+). The patient was diagnosed with Corneal Ulcer Oculi Sinistra with Hypopyon, with the basis of the diagnosis of decreased visual acuity accompanied by conjunctival injection, ciliary injection, corneal edema with epithelial defects in the center, and hypopyon in the left eye. The patient was given Levofloxacin eye drop therapy 1 drop every 2 hours, Chloramphenicol eye drops 1 drop every 12 hours, atropine sulfate eye drops 2x1 left eye drops, vitamin C 500 mg 1 tablet per day, and was advised to check after 3 days.

The patient did not have a check-up after 3 days, but rather one week later. From the anamnesis, it was found that the pain had decreased, and vision was clearer. From the examination of the left eye, it was found that visual acuity improved to 6/15, the palpebra was calm, the conjunctiva was hyperemic, the nodules were positive, the epithelial defect was reduced, the ulcer size was 2.6 mm x 3 mm, and no hypopyon was found. The results of the microbiological examination showed Staphylococcus aureus bacteria. For this second check-up, the patient received Levofloxacin eye drops 1 drop every 3 hours in the left eye, Chloramphenicol eye drops, 1 drop every 12 hours in the left eye,

Methylprednisolone tablets 8 mg (2 tablets in the morning, and 1 tablet in the evening) and Vitamin C tablets 500 mg once a day. The patient was then advised to have a check-up, but never came back.

#### Case 2

A 52-year-old woman living in Jakarta, came to the eye clinic of UKI Hospital on March 23, 2018, with complaints of something stuck in her eye, pain, and decreased vision in her right eye for 5 days. There were no symptoms of nausea, vomiting, or headaches.

The patient had no history of previous eye disease. The patient is a Diabetes Mellitus sufferer who routinely consumes blood sugar-lowering drugs. In the family history, there was no history of metabolic, immunological or malignant diseases.

The results of the visual acuity examination showed that the right eye vision was 1/300 poor light projection, and the left eye vision examination was 6/30 pinhole 6/6. The results of the eyeball pressure examination felt hard (N+). On examination of the right eye, the eyelid appeared calm, the conjunctiva was hyperemic, the secretion was abundant, there was an epithelial defect in the central cornea measuring 7 mm x 8 mm, the anterior oculi camera was difficult to assess, the pupil and lens and light reflex were difficult to assess. On examination of the left eye, the conjunctiva was not hyperemic, the cornea was clear, the anterior segment of the eyeball and the posterior segment were within normal limits.

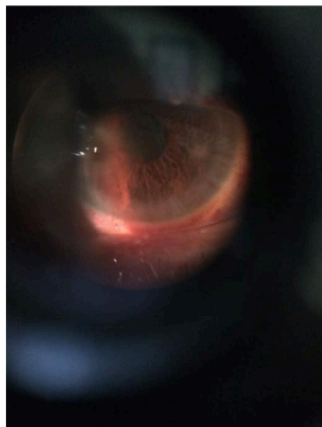


Fig. 2. Slit lamp examination of the anterior segment of the left eye after 1 week of therapy

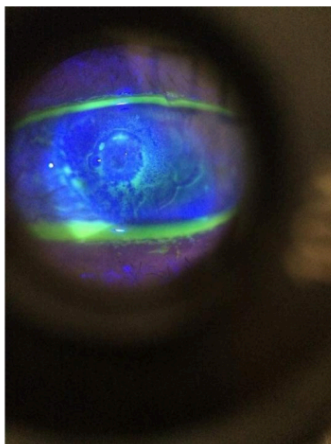


Fig. 3. Corneal ulcer image with fluorescein staining

Corneal swab was performed with topical anesthesia for microbiological examination in the form of a gram and sensitivity culture. This patient was diagnosed with a Right Corneal Ulcer with secondary glaucoma. The patient was given Tobramycin eye drops (Cendo Tobro) 1 drop every 1 hour in the right eye, Gentamycin E.Q

eye ointment every 8 hours in the right eye, Acetazolamide (Glaucan) tablets 250 mg every 12 hours, Potassium L-aspartate (Aspar-K) tablets 1 time a day. One week later, the patient checked into the RSU UKI eye clinic. The visual acuity of the right eye became 3/60, and the size of the corneal ulcer decreased to 5x 4 mm.

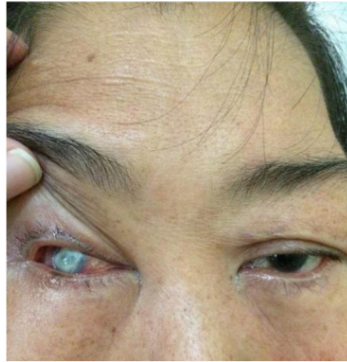

Fig. 4. Image of both patient's eyes, showing epithelial defect in the cornea of the right eye

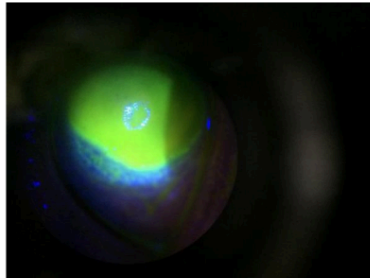


Fig. 5. Fluorescence test on the patient's cornea. Corneal ulcers are seen covering the central cornea to the edge of the limbus

The results of the microbiological examination showed *Klebsiella* Sp as the causative germ and the antibiotic resistance test showed Chloramphenicol as the choice. Tobramycin eye drops were changed to Chloramphenicol (Phenicol) eye drops 1 drop every hour in the right eye, Timolol Maleate 0.5% (Thymol) eye drops 1 drop every 12 hours in the right eye, Ciprofloxacin tablets 500 mg 2x1 tablet.

One week later, the patient complained of severe pain in the right eye, and suddenly, a yellowish-white mucus came out, and the eye looked smaller compared to the right. The patient then checked and found a visual acuity examination of 1/∞ (light perception). The cornea appeared to be perforated in the central part with a shallow anterior chamber. The eyeball seemed hypotonic. The lens and posterior segment could

not be assessed. The patient was diagnosed with a Corneal ulcer with perforation. A conjunctival flap was immediately performed to close the area of corneal perforation. Medication was continued, but by stopping the administration of timolol and adding the painkiller mefenamic acid 3 x 500 mg.

### 3. DISCUSSION

Corneal ulcer or ulcerative keratitis is a process in which the cornea undergoes an inflammatory process and there is a discontinuity of the corneal epithelium (Weisenthal et al., 2014, Nema and Nema, 2008, Khurana, 2007). Symptoms of corneal ulcers are generally pain, decreased visual acuity, red eyes, photophobia, and purulent or mucopurulent discharge (Weisenthal et al., 2014, Kanski, 2007). Often accompanied by hypopyon, a buildup of

inflammatory cells that is seen as a layer of cloudy discharge at the bottom of the anterior ocular chamber. Hypopyon in bacterial corneal ulcers is sterile unless there is a rupture in the Descemet membrane. Some bacteria can provide a typical picture. Eighty percent of cases of corneal ulcers are caused by *Staphylococcus aureus*, *Streptococcus pneumoniae*, and *Pseudomonas* sp. *Pseudomonas aeruginosa* itself is considered the most dangerous ocular pathogen because it can cause corneal perforation in just 72 hours (Srinivasan et al., 1997, Kesehatan, 2013).

In *Staphylococcus aureus* and *Streptococcus pneumoniae* infections, there are usually oval-shaped ulcers that are solid yellowish white and surrounded by a clear cornea. In *Pseudomonas* Sp infections, there are usually irregular ulcers with thick greenish mucopurulent exudate surrounded by a semiopaque cornea (Khurana, 2007). Corneal ulcers usually only occur when the ocular defense mechanism is disrupted or damaged. However, some bacteria can penetrate the normal corneal epithelium, such as *N. gonorrhoeae*, *N. meningitidis*, *C. diphtheriae*, and *H. influenzae* (Kanski, 2007). Pathogenesis of corneal ulcers is divided into 4 stages, namely: 1) Progressive infiltration stage, where there is infiltration of polymorphonuclear cells and lymphocytes into the epithelial layer through the peripheral circulation of the cornea, 2) active ulceration stage, where there is a process of necrosis and shedding of the epithelium, and deeper penetration occurs until it continues to become ulceration depending on the degree of virulence and local defense mechanisms, 3) regression stage, where the ulcer begins to improve and the epithelium begins to grow which is influenced by the production of humoral antibodies and immune defense and treatment management 4) cicatrization stage, where there is a process of progressive epithelialization and thickening of the stroma, if the ulcer is very superficial and only affects the epithelium, it will not leave a cicatrix, and if it affects the Bowman's membrane and stromal lamella, it will leave a cicatrix (Nema and Nema, 2008, Khurana, 2007).

Based on the severity and its relation to the risk of threatening corneal blindness, corneal ulcers can be RST (Rarely Sight Threatening) and PST (Potentially Sight Threatening), where there must be 1 of 3 criteria each, namely PST if 1) There are > 1+ cells in the COA (10 cells or more in a 1-mm beam), 2) Solid infiltrate measuring > 2 mm in the widest diameter, 3) The edge of the

infiltrate is < 3 mm from the center of the cornea (with slit lamp examination); While RST if there are < 1+ cells in the COA (10 cells or more in a 1-mm beam), 2) Solid infiltrate measuring < 2 mm in the widest dimension, 3) The edge of the infiltrate is > 3 mm from the center of the cornea (with slit-lamp examination) (Vital et al., 2007).

As a therapy, topical antibiotic eye drops can achieve a level of penetration which is high in tissue and is the therapeutic method of choice in most cases. Systemic therapy can be performed in cases of spread of scleral or intraocular infection and gonorrhea infection. Broad-spectrum topical antibiotics are used as initial therapy or empirical therapy in cases of corneal ulcers. Cycloplegics can be used to prevent synechiae and reduce pain. Ciprofloxacin 0.3%, ofloxacin 0.3%, and levofloxacin 1.5% are the therapeutic options for bacterial keratitis. When compared with ofloxacin 0.3%, levofloxacin 1.5% showed comparable efficacy with complete reepithelialization and no progressive infiltrate for two consecutive control visits (American Academy of Ophthalmology Cornea/External Disease Panel, 2013).

As in the first case patient, administration of levofloxacin gave good ulcer healing results, as the results of gram examination found gram-positive results, so while waiting for the results of culture and resistance, topical broad-spectrum antibiotic therapy can be given and cefazolin eye ointment is the choice that is considered appropriate. This patient was given Levofloxacin drops, which are third-generation quinolone antibiotics that work by entering the bacterial cell wall and inhibiting the DNA-gyrase enzyme, which functions in bacterial replication, especially gram-positive. Administration was continued after clinical improvement was obtained, indicated by a decrease in ulcer size, increased visual acuity and loss of hypopyon from the anterior ocular chamber. Administration of systemic antibiotics is recommended in acute cases and severe infections where the infection has reached the sclera or signs of impending perforation have been found. Except in cases of gonococcal keratitis (Vital et al., 2007, American Academy of Ophthalmology Cornea/External Disease Panel, 2013).

In general, the initial regimen should be observed within the first 48 hours. Keratitis caused by *Pseudomonas* Sp and other gram-negative organisms, as in the second reported case, can cause acute clinical conditions within 24-48 hours. The difference in virulence properties of



the two ulcer-causing bacteria causes different prognoses in the two patients. Gram-positive infections in the cornea are considered no more dangerous than gram-negative infections. Some gram-negative germs can cause corneal perforation, leading to blindness. Klebsiella, Escherichia coli, and Proteus sp most often attack the cornea that has a history of chronic epithelial disease in the cornea, even without a history of previous trauma. It is known that the second patient is a chronic Diabetes mellitus patient, where this patient has a corneal epithelial and endothelial condition that is not as good as in healthy individuals (Cho et al., 2014, American Academy of Ophthalmology Cornea/External Disease Panel, 2013, Mujaini et al., 2009). Klebsiella Sp is a highly invasive bacterium and can cause corneal perforation. Antibiotic therapy is considered to provide improvement if there is a reduction in: pain, amount of secretion, eyelid edema, and conjunctival injection. In the clinical appearance of ulcers, consolidation and clear boundaries are found. Reduction in infiltrate density in the stromal layer, reduction in cells, fibrin, or hypopyon in the anterior ocular chamber, reepithelialization is seen, and the corneal thinning process stops (American Academy of Ophthalmology Cornea/External Disease Panel, 2013).

Topical therapy should be tapered (gradually decreasing the dose) depending on the clinical response and the virulence of the pathogen. Prolonged use of topical antibiotics can also cause corneal toxicity which ends in corneal melting. If persistent epithelial defects are found and the infection is under surveillance, additional therapy can be given in the form of corneal lubricants, eye ointments, bandage contact lenses, amniotic membrane transplantation or tarsorrhaphy. Most antibiotic eye drops should not be tapered below three or four drops a day because it is considered subtherapeutic and increases the risk of antibiotic resistance. In both reported cases, topical antibiotics as initial therapy were given according to the results of the gram examination. Therapy was evaluated within 3 days and in both cases, the patient only came after one week. The first patient was given additional therapy in the form of oral corticosteroids considering the presence of cells in the anterior ocular chamber, while in the second case, corticosteroids were not given due to the presence of a large ulcer with a depth reaching the stroma.

Administration of steroids in cases of bacterial keratitis is considered to provide benefits in terms of suppressing inflammation, which is expected to reduce corneal scarring related to visual rehabilitation. However, administration of steroids is still controversial because it has a local immunosuppressive effect, inhibition of collagen synthesis, which can accelerate corneal melting and increased intraocular pressure. So that in a study, it was stated that corneal ulcers caused by Pseudomonas and Nocardia are contraindicated for corticosteroid therapy because it aggravates the virulence of bacteria (Khurana, 2007, American Academy of Ophthalmology Cornea/External Disease Panel, 2013). Administration of vitamin C in cases of corneal ulcers, experimentally, has shown that vitamin C has a role in the process of extracellular matrix fibril synthesis in human keratocyte culture tissue which plays a role in the corneal wound healing process. According to research by Cho et al., giving vitamin C supplementation with oral dose of 3 grams/day or intravenously 20 grams/day will reduce the size of corneal opacity in corneal ulcer patients. Differential diagnosis of bacterial corneal ulcers are keratitis caused by other microorganisms (fungi, parasites, viruses, mycobacteria), peripheral ulcerative keratitis, and toxic keratitis (Kanski, 2007, American Academy of Ophthalmology Cornea/External Disease Panel, 2013, McDonald et al., 2014). Complications of corneal ulcers are toxic iridocyclitis, secondary glaucoma, descemetocoele, and corneal perforation.

#### 4. CONCLUSION

Corneal ulcer is an eye infection that is quite common in tropical countries such as Indonesia. It is very important to know the type of germ that causes it through microbiological examination because in addition to being able to provide targeted therapy, the difference like bacterial pathogens will determine the prognosis of the patient's vision in the future.

#### DISCLAIMER (ARTIFICIAL INTELLIGENCE)

Author(s) hereby declare that NO generative AI technologies such as Large Language Models (ChatGPT, COPILOT, etc.) and text-to-image generators have been used during the writing or editing of this manuscript.



## CONSENT

As per international standards or university standards, patient(s) written consent has been collected and preserved by the author(s).

## ETHICAL APPROVAL

As per international standards or university standards written ethical approval has been collected and preserved by the author(s).

## COMPETING INTERESTS

Author has declared that no competing interests exist.

## REFERENCES

- American Academy of Ophthalmology Cornea/External Disease Panel. (2013). *Preferred Practice Pattern® Guidelines: Bacterial Keratitis*. San Francisco, CA: American Academy of Ophthalmology. Retrieved from <https://www.aao.org/ppp>
- Badan Penelitian dan Pengembangan Kesehatan. (2013). *Riset Kesehatan Dasar 2013*. Jakarta: Kementerian Kesehatan RI.
- Biswell, R. (2011). Cornea. In P. R. Eva & E. T. Cunningham (Eds.), *Vaughan & Asbury's General Ophthalmology* (18th ed., pp. 120–126). New York: Lange Medical Books/McGraw-Hill.
- Cho, Y. W., Yoo, W. S., Kim, S. J., Chung, I. Y., Seo, S. W., & Yoo, J. M. (2014). Efficacy of systemic vitamin C supplementation in reducing corneal opacity resulting from infectious keratitis. *Medicine*, 93(23), e125.
- Kanski, J. J. (2007). *Clinical Ophthalmology: A Systematic Approach* (6th ed., pp. 173–180). Edinburgh: Butterworth-Heinemann/Elsevier.
- Khurana, A. K. (2007). *Comprehensive Ophthalmology* (4th ed., pp. 89–100). New Delhi: New Age International.
- McDonald, E. M., Ram, S. F. S., Patel, D. V., & McGhee, C. N. J. (2014). Topical antibiotics for the management of bacterial keratitis: An evidence-based review of high quality randomised controlled trials. *British Journal of Ophthalmology*, 98(11), 1470–1476.
- Mujaini, A. A., Kharusi, N., Thackral, A., & Wali, U. (2009). Bacterial keratitis: Perspective on epidemiology, clinico-pathogenesis, diagnosis, and treatment. *Sultan Qaboos University Medical Journal*, 9(2), 184–196.
- Nema, H. V., & Nema, N. (2008). *Textbook of Ophthalmology* (5th ed., pp. 142–150). New Delhi: Jaypee Brothers.
- Schaefer, F., Bruttin, O., Zografos, L., & Guex-Crosier, Y. (2001). Bacterial keratitis: A prospective clinical and microbiological study. *British Journal of Ophthalmology*, 85(7), 842–847.
- Sridhar, M. S. (2005). *Diagnosis and Management of Microbial Keratitis*. Hyderabad: All India Ophthalmological Society.
- Srinivasan, M., et al. (1997). Epidemiology and aetiological diagnosis of corneal ulceration in Madurai, South India. *British Journal of Ophthalmology*, 81(11), 965–971.
- Upadhyay, M. P., et al. (2001). The Bhaktapur eye study: Ocular trauma and antibiotic prophylaxis for the prevention of corneal ulceration in Nepal. *British Journal of Ophthalmology*, 85(4), 388–392.
- Vital, M. C., Belloso, M., Prager, T. C., & Lanier, J. D. (2007). Classifying the severity of corneal ulcers by using the “1, 2, 3” rule. *Cornea*, 26(1), 16–20.
- Weisenthal, R. W., et al. (2014). *Basic and Clinical Science Course Section 8: External Disease and Cornea* (pp. 148–153). San Francisco: American Academy of Ophthalmology.

**Disclaimer/Publisher's Note:** The statements, opinions and data contained in all publications are solely those of the individual author(s) and contributor(s) and not of the publisher and/or the editor(s). This publisher and/or the editor(s) disclaim responsibility for any injury to people or property resulting from any ideas, methods, instructions or products referred to in the content.

© Copyright (2025): Author(s). The licensee is the journal publisher. This is an Open Access article distributed under the terms of the Creative Commons Attribution License (<http://creativecommons.org/licenses/by/4.0>), which permits unrestricted use, distribution, and reproduction in any medium, provided the original work is properly cited.

Peer-review history:

The peer review history for this paper can be accessed here:  
<https://pr.sdiarticle5.com/review-history/135845>

# CornealUlcerwithIntraocular

## ORIGINALITY REPORT

17%

SIMILARITY INDEX

15%

INTERNET SOURCES

11%

PUBLICATIONS

9%

STUDENT PAPERS

## PRIMARY SOURCES

1	Submitted to SUNY Downstate Health Sciences University Student Paper	2%
2	<a href="http://www.journalsocialstudy.com">www.journalsocialstudy.com</a> Internet Source	2%
3	<a href="http://repository.kyu.ac.ke">repository.kyu.ac.ke</a> Internet Source	2%
4	<a href="http://www.aao.org">www.aao.org</a> Internet Source	2%
5	<a href="http://www.coursehero.com">www.coursehero.com</a> Internet Source	1%
6	<a href="http://ijrp.org">ijrp.org</a> Internet Source	1%
7	"Encyclopedia of Ophthalmology", Springer Science and Business Media LLC, 2018 Publication	1%
8	<a href="http://archive.article4submit.com">archive.article4submit.com</a> Internet Source	1%
9	<a href="http://www.ncbi.nlm.nih.gov">www.ncbi.nlm.nih.gov</a> Internet Source	1%
10	Mark C Vital, Marcel Belloso, Thomas C Prager, Jeffrey D Lanier. "Classifying the Severity of Corneal Ulcers by Using the "1, 2, 3" Rule", Cornea, 2007 Publication	1%

11 J Katz. "A randomised trial of povidone-iodine to reduce visual impairment from corneal ulcers in rural Nepal", British Journal of Ophthalmology, 2004 1 %  
Publication

---

12 Submitted to University College London 1 %  
Student Paper

---

13 Lawson Ung, Yvonne Wang, Mark Vangel, Emma C. Davies, Matthew Gardiner, Paulo J.M. Bispo, Michael S. Gilmore, James Chodosh. "Validation of a Comprehensive Clinical Algorithm for the Assessment and Treatment of Microbial Keratitis", American Journal of Ophthalmology, 2020 1 %  
Publication

---

14 peerj.com 1 %  
Internet Source

---

Exclude quotes On

Exclude matches < 1%

Exclude bibliography On