



# SERTIFIKAT

DIBERIKAN KEPADA

**DR. dr. AGO HARLIM, MARS, Sp.KK**

ATAS PARTISIPASINYA DALAM

WORKSHOP LASER THERAPY FOR PHOTODAMAGE SKIN

DENGAN TEMA

*Sun And Skin - Risk And Benefit*

SEBAGAI

**PEMBICARA**

**BALIKPAPAN - KALIMANTAN TIMUR**

**16 - 18 NOVEMBER 2018**



SK PB IDI Nomor :

Peserta	: 4	SKP
Pembicara	: 12	SKP
Moderator	: 4	SKP
Panitia	: 2	SKP

**Dr. RA Sekar Djalningrum, SpKK, FINSDV**

KETUA PERDOSKI BALIKPAPAN

**Dr. Regina Sybwa Costarina, SpKK**

KETUA PANITIA

**From:** andravita mitaart sinasbalikpapan2018@yahoo.com  
**Subject:** Permohonan CV  
**Date:** 29 January 2018 11.47  
**To:** Ago Harlim agoharlim@yahoo.com

---



Kepada Yth.  
Dr. dr. Ago Harlim, MARS, SpKK  
di -  
Tempat

Dengan Hormat,  
Kami ucapkan terima kasih kembali atas kesediaan Dokter menjadi Instruktur Workshop pada acara SINAS dan Workshop PERDOSKI Cabang Balikpapan. Untuk itu kami memohon agar dapat mengirimkan Curriculum Vitae demi kelengkapan administrasi kami. Demikian yang dapat kami sampaikan. Kurang lebihnya kami mohon maaf. Dan kami ucapkan terima kasih.

Hormat Kami,  
Sekretariat SINAS PERDOSKI Cab. Balikpapan





Simposium, Workshop & Bakti Sosial

# Sun and Skin: Risk and Benefit

**DR. Dr. Ago Harlim, MARS, Sp.KK**  
Pembicara

**Hotel Gran Senyur**  
**Balikpapan, 16-18 November 2018**



# Sun and Skin: Risk and Benefit

Balikpapan, 16-18 November 2018

## SYMPOSIUM

Jum'at, 16 November 2018

08.00 - 17.00	<b>Daftar ulang</b>	
08.00 - 08.30	<b>Pembukaan</b>	
08.30 - 10.00	<b>SESSION I : All ABOUT ULTRAVIOLET</b>	
	Moderator: Dr. Adhlmukti T. Sampurna, SpKK, FINS-DV	
08.30 - 08.50	Sunrays: Natural and Artificial	Dr. Arif Budianto, SpKK (K), FINS-DV, FAADV
08.50 - 09.10	Sun And Skin: Achieving And Balancing For Good Health	DR. Dr. Cita Rosita Praluswa, SpKK (K), FINS-DV, FAADV
09.10 - 09.30	Photodamage Skin From Dermatopathology Perspective	Dr. Hendra Gunawan, SpKK (K), Ph.D, FINS-DV, FAADV
09.30 - 09.50	Ethical Review: Beauty Is Not Always About White Skin	Prof. DR. Dr. Endang Suteja, SpKK (K), FINS-DV, FAADV
09.50 - 10.00	Diskusi	
10.00 - 10.15	<b>Coffee Break</b>	
10.15 - 11.45	<b>SESSION II : PHOTOSENSITIVITY DISEASES: FROM MECHANISM TO MANAGEMENT</b>	
	Moderator: dr. RA Sekar Djatiningrum, SpKK, FINS-DV	
10.15 - 10.35	Phototoxicity vs Photoallergy	Prof. DR. Dr. Endang Suteja, SpKK (K), FINS-DV, FAADV
10.35 - 10.55	Solar Urticaria	Dr. Hartati Purbo Dharmadji, SpKK, FINS-DV, FAADV
10.55 - 11.15	Photocontact Dermatitis	Dr. Sri Awalia Febriana, SpKK, M.Sc, PhD
11.15 - 11.35	Eczematous Photodermatitis	Prof. DR. Dr. Retno Widowati, SpKK (K), FINS-DV, FAADV
11.35 - 11.45	Diskusi	
11.45 - 13.00	<b>ISHOMA</b>	



13.00 - 14.30	<b>SESSION III : PHOTOIMMUNOLOGY DISEASES: FROM MECHANISM TO MANAGEMENT</b> Moderator: DR. Med. Dr. Retno Danarti, SpKK, FINS DV	
13.00 - 13.20	Mechanism Of Photoimmunology	Prof. DR. Dr. Oki Suwarsa, SpKK (K), M.Kes, FINS DV, FAADV
13.20 - 13.40	Psoriasis And Sun: Risk And Benefit	DR. Dr. Soenardi, SpKK (K), FINS DV, FAADV
13.40 - 14.00	Chronic Sun Exposure In Cutaneous Lupus Erythematosus Lead To Systemic Process	Dr. Endi Novianto, SpKK (K), FINS DV
14.00 - 14.20	Induction And Exacerbation Pemphigus Due To Sun Exposure	Prof. Dr. Pieter Levy Suling, M.Sc, SpKK (K)
14.20 - 14.30	Diskusi	
14.30 - 16.00	<b>SESSION IV : THE BENEFITS OF VITAMIN D AND ULTRAVIOLET FOR SKIN AND OTHER ORGANS</b> Moderator: Prof. DR. Dr. Oki Suwarsa, SpKK (K), M.Kes, FINS DV, FAADV	
14.30 - 14.50	Vitamin D As Immunomodulator	Prof. DR. Dr. Siti Setiati, SpPD, KGer, Mepid
14.50 - 15.10	Oral Vitamin D As A Successful Combination Therapy With Narrowband UVB In Adult Vitiligo Patients	DR. Dr. Reiva Farah Dwiyan, SpKK, M.Kes, FINS DV
15.10 - 15.30	Skin Tanning: Risk Or Benefit?	DR. Dr. Puguh Riyanto, SpKK (K), FINS DV, FAADV
15.30 - 15.50	Diskusi	
15.50 - 16.00	<b>Coffee Break</b>	
16.00 - 17.30	<b>SESSION V : IRRADIATION ULTRAVIOLET EXACERBATED DISEASES</b> Moderator: Dr. Endi Novianto, SpKK (K), FINS DV	
16.00 - 16.20	The Role Of Sun Exposure To Acne And Rosacea	Prof. Dr. Anis I. Anwar, SpKK (K), FINS DV, FAADV
16.20 - 16.40	The Role Of Sunrays In Atopic Dermatitis, Seborrhoeic Dermatitis And Pityriasis Rubra Pilaris	DR. Med. Dr. Retno Danarti, SpKK, FINS DV
16.40 - 17.00	Recent Advances In Melasma	DR. Dr. M. Yulianto Listiawan, SpKK (K), FINS DV, FAADV
17.00 - 17.20	Stem Cell For Photoaging Skin Treatment In Clinical Application	Prof. DR. Dr. Johanes W Widodo, SpKK (K), FINS DV, FAADV
17.20 - 17.30	Diskusi	



13.00 - 14.30	<b>SESSION III : PHOTOIMMUNOLOGY DISEASES: FROM MECHANISM TO MANAGEMENT</b> Moderator: DR. Med. Dr. Retno Danarti, SpKK, FINS DV	
13.00 - 13.20	Mechanism Of Photoimmunology	Prof. DR. Dr. Oki Suwarsa, SpKK (K), M.Kes, FINS DV, FAADV
13.20 - 13.40	Psoriasis And Sun: Risk And Benefit	DR. Dr. Soenardi, SpKK (K), FINS DV, FAADV
13.40 - 14.00	Chronic Sun Exposure In Cutaneous Lupus Erythematosus Lead To Systemic Process	Dr. Endi Novianto, SpKK (K), FINS DV
14.00 - 14.20	Induction And Exacerbation Pemphigus Due To Sun Exposure	Prof. Dr. Pieter Levy Suling, M.Sc, SpKK (K)
14.20 - 14.30	Diskusi	
14.30 - 16.00	<b>SESSION IV : THE BENEFITS OF VITAMIN D AND ULTRAVIOLET FOR SKIN AND OTHER ORGANS</b> Moderator: Prof. DR. Dr. Oki Suwarsa, SpKK (K), M.Kes, FINS DV, FAADV	
14.30 - 14.50	Vitamin D As Immunomodulator	Prof. DR. Dr. Siti Setiati, SpPD, KGer, Mepid
14.50 - 15.10	Oral Vitamin D As A Successful Combination Therapy With Narrowband UVB in Adult Vitiligo Patients	DR. Dr. Reiva Farah Dwiyan, SpKK, M.Kes, FINS DV
15.10 - 15.30	Skin Tanning: Risk Or Benefit?	DR. Dr. Puguh Riyanto, SpKK (K), FINS DV, FAADV
15.30 - 15.50	Diskusi	
15.50 - 16.00	<b>Coffee Break</b>	
16.00 - 17.30	<b>SESSION V : IRRADIATION ULTRAVIOLET EXACERBATED DISEASES</b> Moderator: Dr. Endi Novianto, SpKK (K), FINS DV	
16.00 - 16.20	The Role Of Sun Exposure To Acne And Rosacea	Prof. Dr. Anis I. Anwar, SpKK (K), FINS DV, FAADV
16.20 - 16.40	The Role Of Sunrays In Atopic Dermatitis, Seborrhoeic Dermatitis And Pityriasis Rubra Pilaris	DR. Med. Dr. Retno Danarti, SpKK, FINS DV
16.40 - 17.00	Recent Advances In Melasma	DR. Dr. M. Yulianto Listiawan, SpKK (K), FINS DV, FAADV
17.00 - 17.20	Stem Cell For Photoaging Skin Treatment In Clinical Application	Prof. DR. Dr. Johanes W Widodo, SpKK (K), FINS DV, FAADV
17.20 - 17.30	Diskusi	



# SYMPOSIUM

Sabtu, 17 November 2018

08.00 - 17.00	<b>Daftar Ulang</b>	
08.00 - 09.30	<b>SESSION VI : SUN AND SKIN TUMORS</b> Moderator: Dr. Abraham Arimuko, SpKK, FINS-DV, FAADV	
08.00 - 08.20	The Role of UV Irradiation in Carcinogenesis	Prof. DR. Dr. Johannes W Widodo, SpKK (K), FINSDV, FAADV
08.20 - 08.40	Benign Skin Tumor Due To Sun Exposure	DR. Dr. Sri Lestari, SpKK, FINSDV, FAADV
08.40 - 09.00	Precancerous And Skin Cancer Due To Sun Exposure	Dr. Danang Triwahyudi, SpKK, FINSDV, FAADV
09.00 - 09.20	Surgical Management For Skin Cancer	Dr. Adhimukti T. Sampurna, SpKK, FINSDV
09.20 - 09.35	Diskusi	
09.35 - 10.50	<b>SESSION VII : PHOTOTHERAPY AND LASER THERAPY</b> Moderator: dr. Nuriah, SpKK, FINS-DV	
09.35 - 09.55	Recent Advances In Phototherapy For Psoriasis	DR. Dr. Soenardi, SpKK (K), FINSDV, FAADV
09.55 - 10.15	Phototherapy In Vitiligo: 5 Years Experience In Jakarta	DR. Dr. Tjut Nurul Alam Jacob, SpKK (K), FINSDV, FAADV
10.15 - 10.35	Laser Therapy for Atopic Dermatitis And Psoriasis: Myth Or Fact?	Dr. Natalia Wahyudi, SpKK
10.35 - 10.50	Diskusi	
10.50 - 11.05	<b>Coffee Break</b>	
11.05 - 12.20	<b>SESSION VIII : NEW CONCEPT IN SUN PROTECTION</b> Moderator: DR. Dr. Tjut Nurul Alam Jacob, SpKK(K), FINS-DV, FAADV	
11.05 - 11.25	Mechanism Of Sunscreen	DR. Dr. Cita Rosita Praluswa, SpKK (K), FINSDV, FAADV
11.25 - 11.45	Enhancing Skin Ultraviolet Protection Using The Unique Photochemical Properties	Dr. Abraham Arimuko, SpKK, FINSDV, FAADV
11.45 - 12.05	Choosing Sun Screen Based On MED Study Related To Indonesians Photoskin Type	Dr. Srie Prihianti, SpKK, PhD, FINSDV, FAADV
12.05 - 12.20	Diskusi	
12.20 - 12.35	<b>Penutupan (Doorprize)</b>	
12.35 - 13.20	<b>ISHOMA</b>	



# Workshop

## Sabtu, 17 November 2018

13.20 - 16.50	<b>WORKSHOP I : PHOTOPATCH TESTING</b> Moderator: DR. Dr. Tjut Nurul Alam Jacoeb, SpKK (K), FINS-DV, FAADV	
13.20 - 13.50	How to Diagnose Photo Contact Dermatitis	Dr. Sri Awalia Febriana, SpKK, M.Sc, PhD
13.50 - 14.20	All About Photopatch Test	Dr. Niken Indrastuti, SpKK (K)
14.20 - 16.50	Hands On / Video Photopatch Test	Instruktur
13.20 - 17.20	<b>WORKSHOP II : LASER THERAPY FOR PHOTODAMAGE SKIN</b> Moderator: Dr. Rani Rachmawati, SpKK	
13.20 - 13.50	Long Pulsed Laser – Nd:YAG For Acne and Rosacea Therapy	DR. Dr. Ago Harlim, MARS, SpKK
13.50 - 14.20	Long Pulsed Laser – Nd:YAG For Dermatitis and Psoriasis Therapy	Dr. Natalia Wahyudi, SpKK
14.20 - 17.20	Hands On: Smooth Laser	Instruktur
13.20 - 16.50	<b>WORKSHOP III : BIOLOGIC AGENT FOR PSORIASIS TREATMENT</b> Moderator: dr. Regina Sylvia Costarina, SpKK	
13.20 - 16.50	Biologic in Psoriasis-Changing the paradigm and patient outcomes	Dr. Endi Novianto, SpKK, FINSKV
	Practical Aspect of Biologic Use-Secukinumab in action	Prof. Dr. dr. Benny Effendi Wiryadi, Sp.KK (K)
13.20 - 16.50	<b>WORKSHOP IV : ALL ABOUT SUPERFICIAL CHEMICAL PEELS</b> Moderator: dr. Adria Rusvita, SpKK	
13.20 - 13.50	What is Chemical Peels	Dr. RA Sekar Djatiningrum, SpKK, FINSKV
13.50 - 14.20	Indication and Contraindication of Superficial Chemical Peels	Dr. Nuriah, SpKK, FINSKV
14.20 - 17.20	Hands On: Superficial Chemical Peels	Instruktur
17.00 - 17.20	<b>Coffee Break</b>	

# Bakti Sosial

## Minggu, 18 November 2018

08.00 - 11.00	<b>PENYULUHAN</b> MC : - Dr. Andravita Fenti Mitaart, SpKK - Dr. Ismail, M.Sc, SpKK	
	Apa Itu Sinar Matahari Dan Efeknya Bagi Tubuh	Dr. Regina Sylvia Costarina, SpKK
	Pembagian Sample Tabir Surya Gratis	



# **Laser therapy for Photodamage**

Ago Harlim

Universitas Kristen Indonesia

Balipapan, 2018

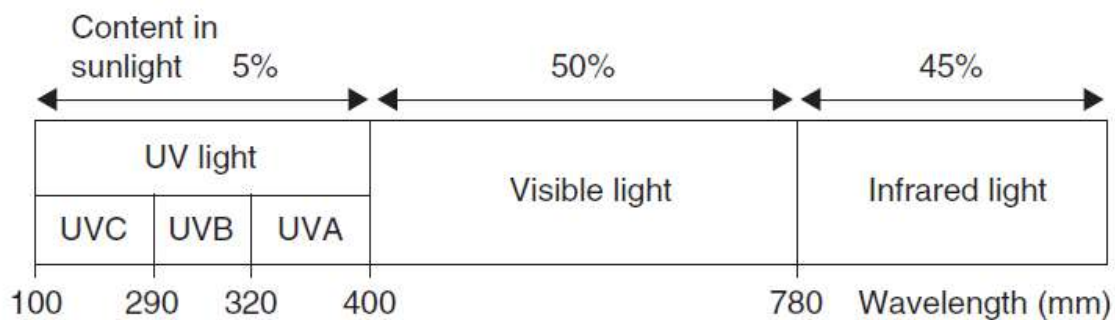
## **1. introduction**

Photodamage refers to the changes in the skin that occur after prolonged exposure to UV irradiation. Photoaging refers to alterations in the skin that resemble the effects of age caused by sun exposure. Aging is a constant and inevitable process, wherein intrinsic aging and photoaging are two independent clinically and biologically distinct processes that simultaneously affect the skin. Intrinsic aging is composed of slow, irreversible tissue degeneration while photoaging (extrinsic aging) is a result of exposure to outdoor agents, mainly UV irradiation. The effects of UV radiation (UVR) on skin are profound and are estimated to account for up to 90% of visible skin aging. It has been studied and demonstrated that UV irradiation inhibits the synthesis of collagen and induces collagen degradation.<sup>1</sup>

Not only can excessive solar exposure accelerate and intensify skin aging, it also can lead to serious health risks such as cutaneous neoplasms. UV radiation is a complete carcinogen, as it not only initiates cancer through DNA mutation but also promotes cancer growth through the inflammatory processes inherent in cumulative UV exposure. It is estimated that 90% of all skin cancers are directly related to sun exposure.<sup>1</sup>

## **2. UV Light**

Sunlight is composed of a continuous spectrum of electromagnetic radiation that is divided by wavelength into UV light (5% content in sunlight), visible light (50%), and infrared (45%). UV is further divided into UVC (100-280 nm), which is absorbed by the ozone layer, UVB dan UVA. UVB(290-280 nm) represents only 0,3% of the sun's emission reaching the ground; however, it is the primary cause of sunburn and skin cancer. More than 99% of UVB reaches the eye and is absorbed by the anterior structure of the eye, causing corneal disorder such as pterygium and photokeratitis. Acute effects of UVB in the skin include erythema, edema, pigment darkening, and thickening of the epidermis and the dermis; chronic effects include immunosuppression, photo-aging, and photocarcinogenesis.<sup>4</sup>



**Figure 2.1** Solar Radiation spectrum<sup>4</sup>

UVA represents 90% of the total UV radiation reaching the earth's surface. It penetrates deeper in the dermis and into the eye than UVB and is responsible for degenerative processes of the retina. UVA is further divided into two regions: UVA2 (320-340 nm) with higher erythemogenic potential and UVA1 (340-400nm), which causes photosensitivity, local immunosuppression, and photo-aging. UVA is responsible for immediate pigment darkening, which disappears within 2 hours and has chronic effects similar of those of UVB.<sup>4</sup>

### 3. Photodamage, Photo-Aging, and UV

Photodamage refers to the changes in the skin that occur after prolonged exposure to UV irradiation. Photoaging refers to alterations in the skin that resemble the effects of age caused by sun exposure.<sup>1</sup> There are two types of skin aging: intrinsic aging and extrinsic aging (photo-aging). Intrinsic skin aging is related to natural biological aging processes in sun-protected skin. Intrinsically aged skin appears smooth, pale, and finely wrinkled in contrast to photo-aged skin, which is coarsely wrinkled and frequently characterized by abnormal pigmentation and telangiectasias. The greatest differences between intrinsically aged and photo-aged skin occur within the dermis and involve degradation of a number of extracellular matrix proteins, including collagen and elastic fibers.<sup>7</sup>

Photo-aging is the effect of long-term UV exposure and sun damage superimposed on intrinsically aged skin and affects lighter-skinned individuals more severely. The face, neck and dorsum of hands and forearms are most commonly affected. Many skin functions that decline with age show an accelerated decline in photo-aged skin. Clinical characteristic of photo-aged skin include dyspigmentation, skin laxity, a yellow hue, wrinkles, telangiectasia, a leathery appearance, and cutaneous malignancies.<sup>8</sup>



### **3. Epidemiology aspects**

In human skin, solar UV radiation can cause pigmentation, photoaging, skin cancer, and the less frequent but very dangerous malignant melanoma. Basal Cell Carcinoma (BCC) is responsible for nearly 80% of all non-melanoma skin cancer cases, most common in Caucasian populations and rare in Asians and Black races of Africa. SCC is the second most common type of non-melanoma skin cancer. It contributes to about 20% of all detected skin cancer cases. Cutaneous melanoma arises from mutated melanocytes. Melanocytes are also known as the pigment-producing cells of skin. It contributes nearly 75% of all skin cancer mortality and 3–5% of all cutaneous cancers<sup>9</sup>

Photocarcinogenesis is predominantly a disease of people of European origin. It is observed that the rate of melanoma formation is very low in Asians in the United States which is expected to rise in the next 50 years. Its incidence is some 20-folds higher in Whites than Blacks. Non-melanoma skin cancers, BCC and SCC, are rare in non-White populations. In populations of European origin, non-melanoma skin cancer especially SSC, incidence rates are lower in people with ethnically darker skins.<sup>9</sup>

### **4. Pathophysiology**

Photodamage derives from the derangements induced by UVR. The onslaught of biochemical reactions and photon-induced damage that occur in the epidermis and dermis translate to the visible manifestations of wrinkles and pigmentary abnormalities. The main facet of wrinkle formation is damage to and remodeling of the extracellular matrix caused by matrix metalloproteinases (MMPs) and other proteases. Matrix metalloproteinases are naturally existing molecules whose function is to remodel the extracellular matrix during times of skin development and wound healing. Matrix metalloproteinases have affinities toward specific components of the dermis and epidermis. The constituents of the dermis include type I and III collagen, elastins, proteoglycans, and fibronectins. Collagen fibers contribute to most of the strength and elasticity of the skin. Matrix metalloproteinases-9 preferentially degrades elastin and fibrillin while MMP-2 degrades collagen type III and components of the dermal-epidermal junction.<sup>1</sup>

**Tabel 4.1** Physiologic Derangements in Photodamage<sup>1</sup>

- Altered composition of dermal ECM with disorganized collagen fibers and imperfect repair, leading to wrinkle formation, decreased skin elasticity, greater skin fragility, and reduced wound healing
- Accumulation of dystrophic elastic fibers in dermis after alteration by MMPs and other proteases, leading to solar elastosis<sup>22</sup>
- Diminished number of collagen fibers in papillary dermis
- Reduced expression of fibrillin, an important component of oxytalan (connects superficial dermal elastic fibers to those in the deeper dermal layers)<sup>23</sup>
- Decreased type VII collagen, which weakens the connection between the lamina densa and papillary dermis<sup>24</sup>

---

Abbreviations: ECM, extracellular matrix; MMP, matrix metalloproteinase.

In addition, there are various proteolytic enzymes such as gelatinases and stromelysins that further degrade collagen after cleavage by collagenase. Collagenase messenger RNA expression is up-regulated throughout the epidermis and dermis when exposed to UVR.<sup>3</sup> UVR also is able to increase MMP expression indirectly by activation of transcription factor activator protein 1, which increases transcription of MMP genes. Coincidentally, activator protein 1 also stimulates the production of tissue inhibitor of MMP-1. A substantial portion of MMPs are synthesized in the epidermis and then migrate further down toward the dermis.<sup>3</sup> There is an observation of a temporal pattern of the level of MMP expression, such that it seems to be maximal after multiple UVR exposures. A hypothesis regarding MMP-induced collagen fragments states that photodamage can lead to the further suppression of collagen synthesis by fibroblasts. It has been suggested that the presence of damaged collagen may act in some way to down-regulate collagen synthesis by cells that are inherently capable of making collagen.<sup>1</sup>



**Tabel 4.2** Additional Components Involved in Photodamage<sup>1</sup>

Factors Affecting Photodamage	Role	Mechanism or Action
TGF- $\beta$	Regulates cell differentiation, growth, and repair	UVR down-regulates number of TGF- $\beta$ type II receptors <sup>27</sup>
	Aids the induction of procollagen and fibronectin synthesis in the dermis <sup>26</sup>	Repression of TGF- $\beta$ binding to its receptor is seen in ~90% of photoaged skin <sup>27</sup>
ROS	Causes connective tissue degradation <sup>28-30</sup>	UVR generates ROS in the dermis and epidermis <sup>32</sup>
	Inactivates naturally occurring tissue inhibitors of metalloproteinases <sup>31</sup>	UVB radiation is most damaging to the epidermis <sup>33,34</sup>
		UVA radiation penetrates to the dermis, causing more oxidative stress <sup>33,34</sup>
		UVR depletes antioxidants <sup>35</sup>
		ROS create mutations in mtDNA, disrupt the function of the mitochondria, and induce MMPs <sup>36-39</sup>
	mtDNA mutations can persist for >1.5 years after generation and can be used as an extended marker of UVR <sup>40</sup>	
Neutrophils and mononuclear cells	Causes inflammatory response due to release of ROS, cytokines, and MMPs <sup>41</sup>	Recruited into the epidermis and dermis in response to the damage caused by UVR <sup>42</sup>
	Potentially activates certain proteases, such as MMP-1 and MMP-9 <sup>42</sup>	UVR-activated nuclear factor $\kappa$ B drives neutrophil attraction <sup>43</sup>
Estrogen	May be involved in the maintenance of the extracellular matrix through the increased production of hyaluronic acid and collagen <sup>44,45</sup>	
Smoking		Leads to altered wound healing and cancer advancement <sup>46</sup>
		Smokers have 4.7 times more risk for developing facial wrinkles compared with nonsmokers <sup>47</sup>
		Smoke extract is able to increase MMP expression in fibroblasts <sup>48</sup>

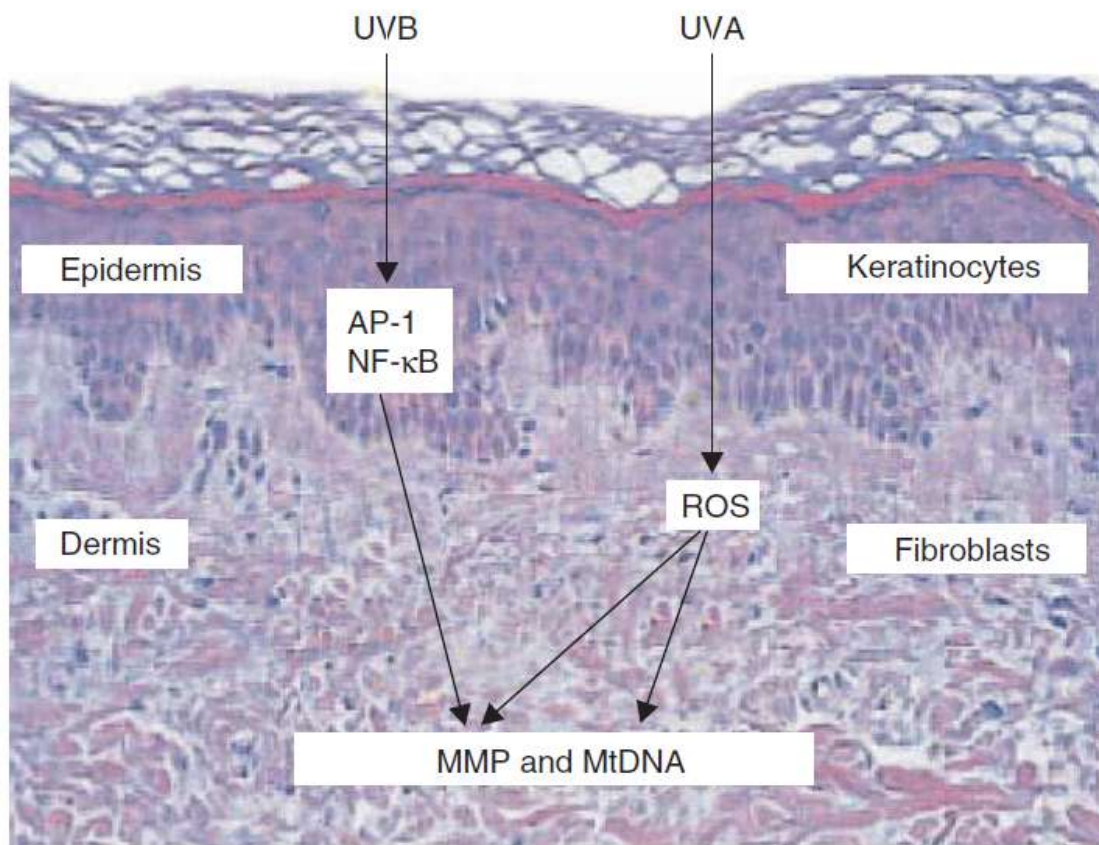
Abbreviations: TGF- $\beta$ , transforming growth factor  $\beta$ ; UVR, UV radiation; ROS, reactive oxygen species; mtDNA, mitochondrial DNA; MMP, matrix metalloproteinase.

UVB affects biochemicals of the skin, the formation of cyclobutane pyrimidine dimers (CPDs) and pyrimidine-pyrimidone photodimers, the photoisomerization of trans- to cis-urocanic acid, and the generation of ROS. UVB is mostly absorbed in the epidermis, where

transcription factors and then MMP expressions are induced. Differing from UVB, UVA reaches into the dermis, where it is absorbed by fibroblasts, generating ROS and leading to the expression of MMP and inducing mutation of mitochondrial DNA (mtDNA).<sup>4</sup>

There is increasing evidence to support the theory that UVA has a greater role in photo damage and photo-aging than UVB, owing to its greater abundance at the earth's surface. UVA is not filtered by window glass, it is less affected by temporal flux than UVB, it is not affected by altitude and atmospheric conditions, and it has deep cutaneous penetration.<sup>4</sup>

However, UVB irradiation is a carcinogen and can induce squamous cell carcinoma in animals. UVB is absorbed by DNA, leading to UV-induced signature mutations. The UV action spectrum for generation of squamous cell carcinoma occurs mainly in the UVB, with a secondary peak activity in the UVA spectrum. UVB is important for tumor initiation, while UVA predominantly causes tumor promotion.<sup>4</sup>



**Figure 4.1** The Role of UV Radiation in Photodamage and Photo-Aging<sup>4</sup>

UVA generates more oxidative stress, is ten times more efficient than UVB causing lipid peroxidation, is more cytotoxic than UVB, and can induce MMP synthesis, augmenting the biologic aggressiveness of skin cancer. The relationship between UVA and cancer involves

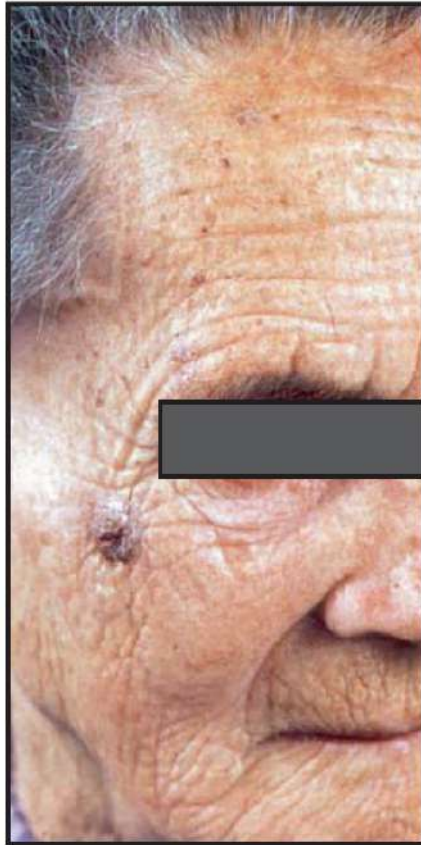

the production of singlet oxygen and DNA nicks and production of 8-hydroxyguanine. The proposed pathophysiology of mitochondrial mutations is exposure to UV light, inducing the generation of ROS and the mutation of mtDNA; this mutation can serve as a memory for damage inflicted to cells or reduce the capacity of the cell to carry out oxidative phosphorylation. This process, in turn, lead to the generation of more ROS.<sup>4</sup>

## **5. Clinical Manifestations**

Long-term exposure of skin to UV radiation disrupts skin's normal organization leading to photoaging (premature aging) and photocarcinogenesis. UV exposure upregulates expression of certain types of enzymes found in human skin such as matrix metalloproteinases (MMPs). These enzymes play essential role in photocarcinogenesis by regulating tumor initiation, growth, angiogenesis, and metastasis . Photocarcinogenesis can be grouped into two major skin cancer classes either non-melanoma or malignant melanoma. Non-melanoma skin cancer is further subdivided into BCC and SCC.<sup>9</sup>

Photodamage from UVR leads to physical manifestations that cause much distress to patients. Photoaging, which is photodamage superimposed on natural aging, has characteristic, sharp features that present in the younger population. Contrastingly, intrinsic aging has qualities that are more subtle and present in older individuals. In intrinsic aging, the skin becomes dry and pale. In addition, there are fine wrinkles with dermal atrophy. However, these changes are in the context of otherwise smooth and unblemished skin. Photodamage manifests as rough skin, mottled hyperpigmentation, and decreased elasticity and recoil. The skin becomes more lax, atrophic, and susceptible to bruising. In addition, the skin may contain telangiectasias (mainly on the nose and cheeks), AKs, purpura, fibrotic depigmented areas, lentiginos, and eventually premalignant and malignant neoplasms. The skin also may have an overall leathery appearance. Irregular pigmentation due to hyperplasia of melanocytes is a hallmark of photodamage. Solar elastosis, which is yellowing and coarsening of the skin, also becomes evident in fair skin, especially in the temporal region. In darker-skinned patients, the effects of photodamage usually are less severe and present at a later age. Melasma is a common pigmented disorder associated with sun exposure and is characterized by well-defined lesions of hyperpigmentation. Although melasma is related to sun exposure, it also is commonly seen in the young population, who may or may not be greatly sun exposed.<sup>1</sup>



**Figure 5.1** Clinical Characteristic of photo-aged skin<sup>4</sup>

The wrinkles of photodamage are coarse and usually on the forehead and periorbital and perioral areas. These wrinkles also are particular because they do not efface when the skin is stretched, while effacement is seen in fine wrinkles.<sup>56</sup> Other lesions associated with chronic sun exposure are seborrheic keratoses, spider nevi, superficial varicose veins, and acne rosacea.<sup>1</sup>

Clinically, the effects of photodamage can be classified into two distinct types: Milian's citrine skin type and atrophic, telangiectatic phenotype. The Milian's citrine skin type is described as deep wrinkles, decreased tautness, leathery skin, blister eruption, decreased wound healing, and cutis rhomboidalis nuchae on the back of the neck. The atrophic phenotype contains telangiectasias and has relatively less wrinkle formation.<sup>1</sup>

## **6 Management of Photodamage-Photoaging**

Photo-aging treatments can be divided into three categories: primary photoprotection, which prevents photodamage before it occurs; secondary, which postpones or attenuates the condition; and tertiary, which treats symptoms to ameliorate negative effects or delay the progress of photodamage. Secondary treatments include retinoic acid, antioxidants, estrogens,



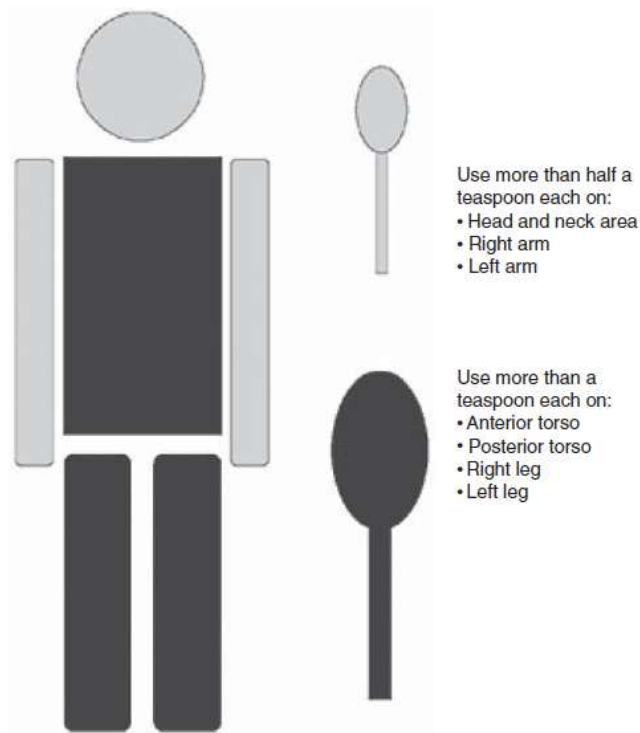
and growth factors, while tertiary treatments include chemical peels, microdermabrasion, ablative lasers, dermabrasion and fractional resurfacing, botulinum toxins, and soft tissue augmentation.<sup>4</sup>

The single most cost-effective primary therapy/photoprotection is sun avoidance between 10am and 4pm, with an emphasis on the role of photoprotective clothing. The UV protection factor (UPF) measures the amount of UV radiation blocked by a fabric; a UPF of 40–50 provides excellent UV protection, transmitting <2.6% of UV radiation. The effectiveness of a fabric is affected by the tightness of the weave, color, fabric shrinkage, and the use of dyes. Hat brims  $\geq 4$  inches (10 cm) are recommended.<sup>4</sup>

### **2.6.1 Photoprotections**

Sunscreens provide protection against UVR and are measured in sun protection factor (SPF). The SPF refers to the total amount of UVR required to create 1 minimal erythema dose on protected skin consisting of a 2-mg/cm<sup>2</sup> area divided by the total amount of UVR required to create 1 minimal erythema dose on unprotected skin. The application of SPF 30 with a 2-mg/cm<sup>2</sup> thickness film distributed evenly over the body allows maximum protection against the harmful effects of UVB (290–320 nm) and UVA (320–340 nm) radiation.<sup>58</sup> Daily outdoor occupations and lifestyles may lead to excessive exposure to UVR. Clinicians recommend photoprotection through the use of sunscreens and sun avoidance. Reducing the amount of UVR absorbed by the skin decreases the likelihood of obtaining AKs, solar elastosis, and squamous cell carcinoma.<sup>59,60</sup> Sun protection factor 15 provides excellent protection against UVB radiation by application on the skin every 40 to 80 minutes, but it does not provide the same results against UVA radiation.<sup>1</sup>

Sunscreen should be applied 15 to 30 minutes before sun exposure to obtain maximum effect, and it should cover the back of the neck, the ears, and hairless regions of the scalp. Greater protection against the sun and longer exposure times can be maintained with higher SPF products, though they must not solely be relied on. Enhanced cosmetic appearance can be achieved by applying sunscreen with a high SPF in combination with topical agents such as lipstick and makeup that also contain a sunscreen. Clothing also can protect against the sun and further prevent photodamage. In general, fabric must be tightly woven to decrease sunlight penetration. Also, a hat with a 4-inch circumference is enough to cover the entire face and neck.<sup>1</sup>



**Figure 6.1** Teaspoon rule for sunscreen application<sup>4</sup>

From physiologic and pathologic points of view, the effects of visible light are different from the effects of UVR. The sensitivity of visible light on the skin can lead to diseases such as porphyria, solar urticaria, polymorphous light eruption, and other idiopathic photodermatoses. A study suggests that visible light exposure may increase pigmentation in people with Fitzpatrick skin types IV to VI. Darker-skinned patients with postinflammatory hyperpigmentation and melasma must use a protecting agent against visible light. Inorganic sunscreen agents (iron oxide, titanium dioxide, zinc oxide) are less susceptible to sensitivity and have better light-blocking effects than organic sunscreen agents.<sup>1</sup>

Although sunscreens are the “gold standard” for UVR protection and consist of chemicals that prevent erythema, reliable skin protection is never attained. Controlled studies, testing the efficacy of sunscreen have shown that the total surface area to which it is applied actually is less than 0.5 mg/cm<sup>2</sup>. The application of sunscreen still causes negative biologic effects in DNA damage, as noticed in thymine dimer formation and 8-hydroxy-2-deoxyguanosine formation. Also, suberythemal levels of irradiation cause the p53 gene induction and UV immunosuppression. The ingredients found in sunscreen contain free radicals that, when activated by UVR, are absorbed by the skin, hence they can cause harm. Antioxidants naturally protect the skin from polluting chemicals and UVR. Both enzymatic and nonenzymatic antioxidative interactions act in conjunction to protect both the intracellular



and extracellular tissues within the skin. Nonenzymatic antioxidants include liquid-phase L-ascorbic acid, glutathione (GSH) in the cellular compartment, vitamin E in membranes, and ubiquinol in mitochondria. Based on molarity, L-ascorbic acid is a predominant antioxidant in the skin. The acidic concentration is 15-fold greater than that of GSH, 200-fold greater than vitamin E, and 1000-fold greater than ubiquinol and ubiquinone. Notably, people with AKs or basal cell carcinoma have lower plasma levels of L-ascorbic acid,  $\alpha$ -tocopherol, and GSH. The application of topical antioxidants to protect the skin against oxidative stress is necessary when the skin is exposed to sunlight. Direct application is the preferred method versus oral and diet supplementations for targeting specific areas of the skin that are deficient in antioxidants.<sup>1</sup>

Antioxidants that are naturally used by the body are considered great for topical use. These include vitamin C, vitamin E, ubiquinol, and GSH. Plants also synthesize several antioxidants (eg, vitamins C and E, flavonoids) to avoid excessive oxidative damage. Topical flavonoids, such as the silybin extract of silymarin, have potent photoprotective properties capable of preventing photodamage to the skin. Studies have shown that silymarin promotes antioxidant reactions, which cause tumor inhibition. Although the mechanisms of action are unknown, studies have demonstrated considerable efficacy.<sup>1</sup>

## **7. Topical Therapy**

Retinoids are vitamin A derivatives that bind to intracellular receptors to cause cellular proliferation and differentiation. One reason to treat the signs of photodamage is to reduce wrinkling. The mechanism of action is the enhanced synthesis of new collagen in the dermis, particularly type I collagen. There also is evidence that it may increase type VII collagen, the anchoring fibers at the dermal-epidermal junction. Topical application of retinoids can lead to wrinkle reduction within a few months. There is variability in response to treatment and those that do not see improvement within 6 months likely are nonresponders. In addition to decreasing wrinkles, retinoids are able to ameliorate roughness and mottled hyperpigmentation. Hyperpigmentation is reduced because retinoids are able to decrease epidermal melanin content.<sup>2</sup>

Aside from their therapeutic effects, retinoids also seem to have a preventive property. A theory of the mechanism of action of retinoids is the inhibition of AP1, thereby decreasing matrix metalloproteinase (MMP) expression. Studies have shown that pretreatment with tretinoin (all-trans-retinoic acid) can inhibit MMP induction by 70% to 80%. It was found to block the expression and activity of collagenase, gelatinase, and stromelysin in the epidermis and dermis. Interestingly, the down-regulation of AP1 did not decrease the production of the

tissue inhibitors of MMPs. Tretinoin actually was found to induce the production of tissue inhibitors of MMP through a different mechanism.<sup>2</sup>

There is a combination cream containing fluocinolone acetonide 0.01%, hydroquinone 4%, and tretinoin 0.05% that is used to treat melasma, which is uneven pigmentation. Hydroquinone is used as a bleaching agent to correct dark spots and unevenness.<sup>2</sup>

$\alpha$ -Hydroxy acids are organic compounds with the ability to disrupt the stratum corneum of the skin, thereby stimulating cell proliferation. The end result is the generation of new, younger-appearing skin. Common  $\alpha$ -hydroxy acids used are lactic acid, malic acid, and glycolic acid. These acids initially damage the stratum corneum, which leads to decreased corneocyte cohesion. Reduced cohesion translates into desquamation or complete severance in sheetlike pieces. This continuous insult leads to epidermal thickening and an increase in dermal glycosaminoglycans content. Transient side effects are erythema and burning after application.<sup>2</sup>

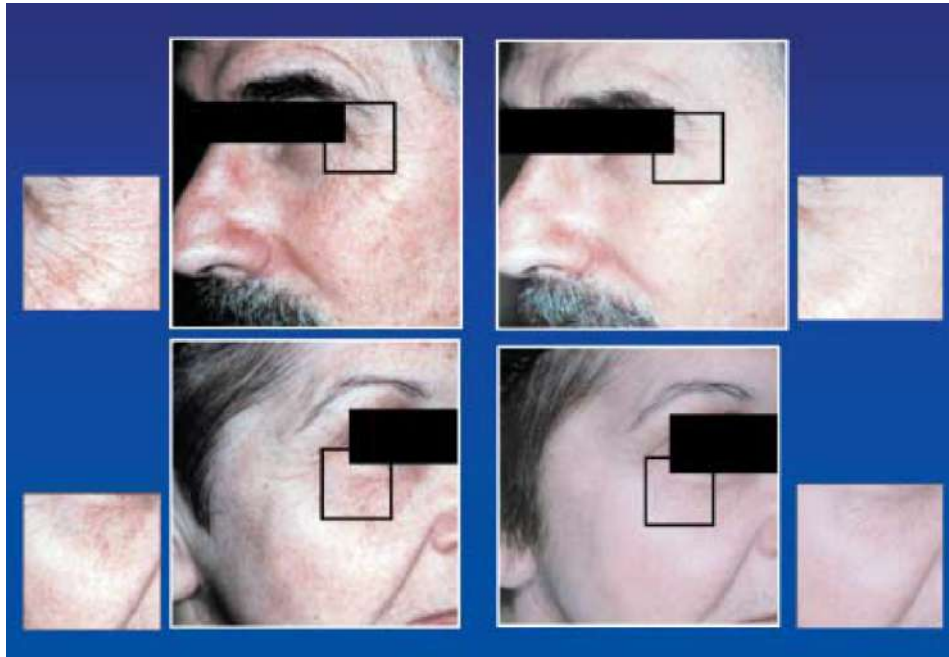Because reactive oxygen species (ROS) are one of the main contributors to photodamage, it is logical that antioxidants are a viable approach to treating these changes. However, there is controversy about whether antioxidant treatment is effective in preventing and reversing photodamage. Administration through an oral route is less than ideal because of difficulties related to absorption from the gastrointestinal tract and the delivery to skin, though this is under debate. Currently, topical antioxidants are preferred. The advantages of topical application lie in greater concentration of the antioxidant in the skin and the extended protection of lasting a few days without concern of rubbing off. The controversial issue that arises is the inherent instability of antioxidants, which make formulating a stable cosmetic compound more difficult. Three major topical antioxidants used today are vitamin C, vitamin E, and selenium.<sup>2</sup>

## **Vitamin C**

Topical vitamin C protects against solar damage primarily as an intracellular antioxidant that deactivates ultraviolet (UV)-induced oxygen free radicals. Vitamin C is itself not a sunscreen, though applying vitamin C definitely decreases erythema and sunburn even when applied After sun exposure. Histological examination confirms this protection: treatment with topical 10% vitamin C decreases the number of abnormal 'sunburn cells' by 40–60% and reduces UV damage to DNA by 62%. Topical vitamin C is also directly anti-inflammatory. The main action of vitamin C on the skin is direct stimulation of collagen synthesis. Vitamin C is an essential cofactor for the two enzymes required in collagen synthesis, prolyl



hydroxylase (which makes the collagen molecule stable) and lysyl hydroxylase (which cross-links the collagen to give structural strength). Another important action of topical vitamin C is increased synthesis of several specific skin-surface lipids. Not only does this mean that vitamin C helps the natural moisturization of the skin, but it also enhances the protective barrier function of the skin.<sup>5</sup>



**Figure 7.1** Correction of photoaging after 1 year of once-daily treatment with 15% vitamin C serum.<sup>5</sup>

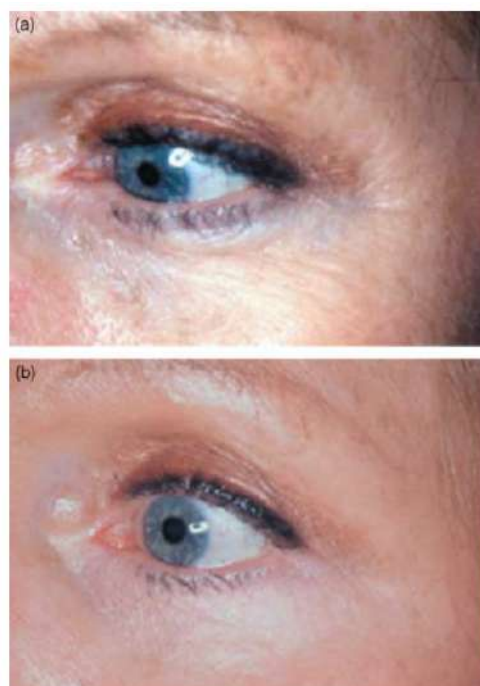Exciting experiments on vitamin C have demonstrated that it also has anti-ageing effects: studies in vitro Compared newborn with elderly (80–90 years old) fibroblasts. The in vitro elderly fibroblasts proliferate at only 1/5 the rate of newborn cells. However, when vitamin C is added, the elderly cells actually proliferate better than normal newborn fibroblasts. Even the newborn fibroblasts enhance proliferation by a factor of 4 when exposed to vitamin C. Not only do fibroblasts increase proliferation, but they also synthesize more collagen in the presence of vitamin. Newborn fibroblasts synthesize a larger percentage of collagen than elderly cells, but when elderly cells are exposed to vitamin C in vitro tissue culture, they produce more collagen than the normal, newborn fibroblasts. The newborn cells double the collagen synthesized. Vitamin C further reverses the adverse appearance of photoaging by inhibiting tyrosinase, thereby fading unattractive solar lentigos. Because ascorbic acid may inhibit elastin biosynthesis it may reduce the solar elastosis of photoaged skin. The remarkable

reversal of photoageing can be appreciated in Fig. 1. After 6 months of once-daily treatment with 15% topical vitamin C, wrinkles were clearly reduced and mottled pigmentation resolved in both of the subjects shown. The skin acquired a healthy, more youthful glow.<sup>5</sup>

### **Vitamin E**

Previous studies have demonstrated protection against acute UV-induced damage of inflammation and hyperpigmentation, as well as protection against the Chronic UV-induced damage of skin cancer even by the various forms of vitamin E which are less metabolically potent when applied topically than the non-esterified Eol.<sup>5</sup>

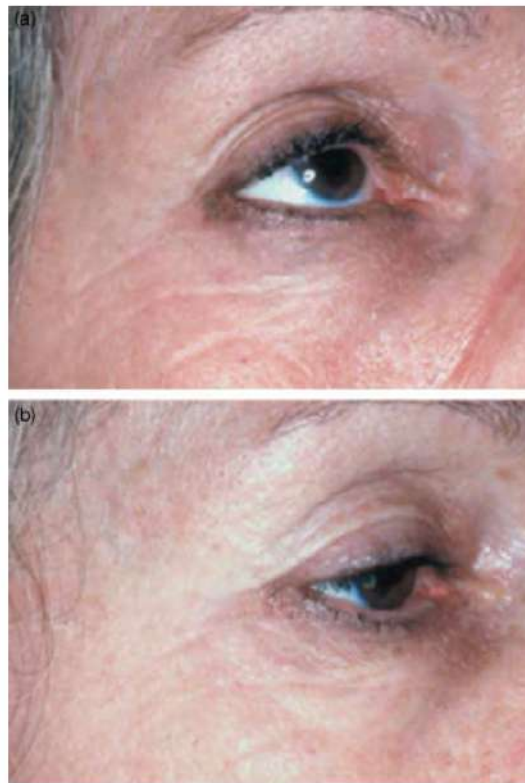
Vitamin E has been shown to dramatically reverse photoageing. Figure 3 shows the dramatic decrease in periorbital rhytides in a 48-year-old woman after 4 months of daily application of d- $\alpha$ -tocopherol (5%). Histological confirmation of correction of the UV-induced epidermal hypertrophy with thickened stratum corneum, increased incidence of damaged 'sunburn cells' in the basal layer, and disruption of dermal collagen and elastin was demonstrated in mice after 8 weeks of similar topical treatment (Burke et al., unpublished observation). Further electron microscopic analysis confirmed correction of collagen and elastin fibre damage and demonstrated repair of UV-induced disruption of the basement membrane anchoring fibrils.<sup>5</sup>



**Figure 7.2** Correction of periorbital wrinkles after 4 months of oncedaily treatment 5% d- $\alpha$ -tocopherol cream.<sup>5</sup>

## Selenium

Selenium has been implicated in reducing carcinogenesis. In animal tumour models, moderate selenium supplementation at levels above the dietary requirements has been shown to decrease the number of tumours induced by several chemical carcinogens and viruses and to reduce the incidence of spontaneous mammary tumours. In addition, selenium supplements have been shown to inhibit the growth of human tumour cell lines in vitro as well as the growth of transplanted tumours in mice and to decrease the mutagenic activity of several known carcinogens.<sup>5</sup>



**Figure 7.3** Correction of periorbital wrinkles after 4 months of oncedaily treatment 0.05% 1-selenomethionine lotion.<sup>5</sup>

Some, but not all, epidemiological studies have found a reduced risk for several kinds of cancer associated with a higher blood concentration of selenium. A decreased selenium concentration and glutathione peroxidase activity in blood and, interestingly, an increase of these parameters in malignant tissue was found in lung cancer patients. A study of 240 non-melanoma skin cancer patients in good general health demonstrated a significantly lower mean plasma selenium concentration than control subjects without skin cancer. In fact, those patients whose blood concentrations were in the lower decile had 4.4 times the incidence of skin cancer as those in the highest decile. In a 10-year prospective study of 1312 patients with a history of



basal cell or squamous cell carcinomas of the skin, selenium treatment did not protect against further development of such skin cancers; however, it did reduce total cancer incidence and the incidence of lung, colorectal and prostate cancer as well as lung cancer mortality.<sup>5</sup>

Topical selenomethionine is highly effective not only in preventing, but also in reversing photoageing. The significant decrease in periorbital rhytides in a 56-year-old woman after 4 months of daily application of l-selenomethionine (0.05%) is shown in Fig. 4. Histological and electron microscopic analysis confirmed repair of epidermal and dermal photoageing.<sup>5</sup>

**Tabel 7.1** Topical Antioxidants for Prevention and Management of Photodamage<sup>2</sup>

TABLE 1		
Topical Antioxidants for Prevention and Management of Photodamage		
Topical Antioxidant	Method of Action	Clinical Improvement
Vitamin C	<p>Anti-inflammatory agent that decreases erythema and sunburn<sup>11</sup></p> <p>Cofactor for 2 essential enzymes involved in collagen synthesis<sup>11</sup></p> <p>Increases transcription rate and stabilizes messenger RNA of procollagen<sup>12</sup></p> <p>Stimulates production of lipids in the skin<sup>13</sup></p>	<p>Improved moisture and natural protective barrier capability of the skin<sup>13</sup></p> <p>Decreased wrinkles, solar lentiginos, solar elastosis, and mottled pigmentation with several months of application<sup>10</sup></p>
Vitamin E	<p>Concentrated mainly in the stratum corneum, the first line of defense in trying to absorb the oxidative stress from UV radiation, effectively depleting vitamin E in doing so<sup>10</sup></p> <p>Decreases immunosuppression<sup>14-16</sup></p> <p>Repairs collagen and elastin; restores basement membrane attachment by correcting anchoring fibers<sup>10</sup></p>	<p>Decreased inflammation, hyperpigmentation, and skin carcinogenesis<sup>15-17</sup></p>
Selenium	<p>Required factor for antioxidant-generating enzymes</p> <p>Glutathione peroxidase and thioredoxin reductase rely on the presence of selenium<sup>17</sup></p> <p>Inhibits carcinogen binding to DNA, DNA oxidation, neoplastic conversion, and cytotoxicity of DNA<sup>10</sup></p> <p>Increases minimal erythema dose and amount of light energy needed to elicit a uniform, demarcated, erythematous reaction<sup>18</sup></p> <p>Decreased plasma selenium levels are associated with increased incidence of nonmelanoma skin cancer<sup>19</sup></p>	<p>Reduced skin carcinogenesis</p> <p>Increased threshold of producing a sunburn reaction</p>

## **8. Oral Therapies and Preventive Treatments**

Green tea is a known antioxidant that has been used in the prevention of photodamage. Various constituents of green tea have potent effects on preventing DNA damage and decreasing alteration of collagen. Green tea phenols (GTP) have been found to prevent UVB-induced cyclobutane pyrimidine dimer formation. Topical GTP on animal models, particularly its most chemopreventive agent (-)-epigallocatechin-3-gallate (EGCG), protects against both local and systemic immune suppression from UVB rays. Katiyar et al<sup>20</sup> also found decreased erythema with GTP application, which they relate to decreased cyclobutane pyrimidine dimer formation as well. EGCG has additional anticancer properties such as inhibiting nitric oxide synthase and tumor necrosis factor. Song et al found an additional benefit of EGCG is that it decreases the expression of Jun protein, a transcription factor of MMP-1. There appears to be a protective effect of EGCG on fibroblasts, which decreases collagen degradation. An additional green tea epicatechin derivative, (-)-epicatechin-3-gallate (ECG), decreases oxidative stress by inhibiting UVA-induced hydrogen peroxide production, rendering a protective effect on keratinocytes. Huang et al also found reversal of hydrogen peroxide-induced cell damage with ECG treatment on a cell model.<sup>2</sup>

$\beta$ -Carotene is a potent dietary antioxidant known as a ROS quencher, particularly oxygen. Another photoprotective effect includes strengthened immunity through heightened macrophage and B-cell and T-cell activities.  $\beta$ -Carotene is more effective in preventing UVA-induced rather than UVB-induced damage. It has been found to offer protection from UVA damage such as decreasing extracellular matrix degradation, reducing oxidative stress, reducing MMP-10 expression, and promoting protease inhibitor expression. A recent systematic review and meta-analysis of randomized control trials evaluating the effectiveness of  $\beta$ -carotene in decreasing cancer risk determined that it does not decrease the incidence of skin cancer. Statistical significance was not achieved and additional randomized control trials are needed to arrive at a conclusion.<sup>2</sup>

## **9. Laser And Light Device**

### **Ablative Laser Resurfacing for Photorejuvenation**

Ablative lasers remain the gold standard for the treatment of photoaging. They work by creating a controlled thermal injury in the dermis that induces new collagen formation. It is important to confine the ablation to a thin surface layer (20–50  $\mu\text{m}$ ) and deliver enough energy to vaporize tissue (5 J/cm<sup>2</sup>) in a time shorter than the thermal relaxation time of the skin (1 ms). Epidermal vaporization with minimal thermal damage to the papillary dermis was first

achieved by 2 different types of CO<sub>2</sub> lasers: the superpulsed laser, whereby the laser tube is pumped electronically to produce high-power, repetitive, short pulses, and a laser controlled with an optomechanical flash scanner. However, because of the associated epidermal ablation with loss of barrier function, these ablative lasers were associated with a long recovery period and adverse effects such as prolonged erythema, substantial downtime, skin discomfort, pigmentary changes, infection, and scarring.<sup>2</sup>

The newer superpulsed lasers cause pure steam vaporization with minimal thermal injury diffusing into adjacent tissue, and deliver pulse energies 5 to 7 times higher than conventional lasers. This therapy follows the principle of selective photothermolysis and maximizes tissue vaporization and pulse duration of less than 1 ms. The newer generation of ablative lasers include the high-energy pulsed or scanned CO<sub>2</sub> lasers, which emit a wavelength of 10,600 nm, and single- or variable-pulse or erbium:YAG (Er:YAG) lasers, which emit a wavelength of 2940 nm and have a dual ablation and coagulation mode. These lasers allow for precise skin vaporization with minimal postoperative complications due to accurately adjustable parameters.<sup>2</sup> Fraxional technique is the best for Asian skin because it can heal without any hyperpigmentation side effect.

### **Nonablative Laser Resurfacing for Photorejuvenation**

Nonablative laser skin rejuvenation was developed to improve different aspects of skin aging. This alternative to ablative laser resurfacing, which was a comparatively invasive procedure associated with various complications, was established by Zelickson et al<sup>41</sup> who found that the purpurogenic doses of the pulsed dye laser (PDL)–induced fibroblast proliferation and neocollagenesis in the papillary dermis. A multicenter, prospective, randomized, controlled, split-face study on 58 individuals where 585-nm PDL was used in the treatment of periorbital rhytides. They concluded that the nonablative lasers induced selective dermal injury while keeping the overlying epidermis intact. The healing process begins after the dermal injury, followed by the production of new type I collagen that aligns in parallel arrays, bringing about the clinical improvement in rhytides, pore size, and scars. Various devices are available to achieve nonablative rejuvenation. They can be subclassified as infrared lasers, visible light lasers, broadband light sources, low-intensity sources, and photodynamic therapy.<sup>2</sup>



## **Infrared Lasers**

These lasers target and heat tissue water without epidermal sparing. With the use of concomitant cooling, the epidermis is protected. Visible Light Lasers Broadband Light Sources. The lasers that belong to this group are 1320-nm Pulsed Nd:YAG, 1450-nm Diode Laser, 1540-nm Erbium:Glass Laser, Q-Switched Nanosecond and Domain 1064-nm Nd:YAG Laser<sup>2</sup>

## **Visible Light Lasers**

Long-Pulsed 532-nm Potassium Titanyl Phosphate Laser— The 532-nm potassium titanyl phosphate (KTP) laser beam is obtained by using a double crystal to halve the 1064-nm wavelength. The KTP laser contains a green light wavelength suitable for treating facial telangiectasias and pigment because it is absorbed by both hemoglobin and melanin. If larger areas such as the entire face are treated with this laser, other benefits of skin texture improvement can be obtained, though not to the same extent as the spot treatment for pigmentary lesions. It is best used for patients with facial telangiectasias and/or UV-induced nonmelasma pigmentation with or without Wrinkles<sup>2</sup>

Pulsed Dye Laser—Originally developed to treat vascular lesions, the 585- and 595-nm PDLs were found to directly affect the adjacent dermis to alter the collagen<sup>2</sup>

## **Broadband Light Sources**

Intense Pulsed Light—Modern IPL devices are sophisticated computer-controlled systems that have minimized the “spectral jitter” encountered with older IPL devices Intense pulsed light devices emit a broad spectrum of light with wavelengths between 515 and 1200 nm. Intense pulsed light can improve telangiectasia, redness, lentiginos, dyspigmentation, and fine wrinkling. It has the advantages of larger spot size and ease of use. If used by experienced hands, there is minimal downtime for the patient<sup>2</sup>

Light-Emitting Diode—Light-emitting diodes (LEDs) are complex semiconductors that convert electrical current into incoherent narrow spectrum lights ranging from UV to the visible and infrared wavelengths<sup>2</sup>

## **10. Photodynamic Therapy**

Photodynamic therapy consists of the application of a photosensitizing agent on the skin followed by an incubation period and then exposure to a light source. The photosensitizers

are metabolized to protoporphyrin IX (PpIX) in the mitochondria. The maximum absorption of PpIX is at 410, 630, and 690 nm. When this PpIX is exposed to light, a photochemical reaction is set off, generating cytotoxic ROS that brings about cell damage. The photosensitizers localize themselves mostly in proliferating cells such as neoplastic cells rather than in healthy tissue, thus making photodynamic therapy a useful modality for treating precancerous lesions and certain cancers. Photodynamic therapy with aminolevulinic acid and blue light as the light source, and methylaminolevulinic acid with red light, has been approved by the US Food and Drug Administration for treatment of actinic keratoses. Photodynamic therapy also has been used for photorejuvenation because it has been shown to improve signs of photoaging<sup>2</sup>

## **11. Radiofrequency**

Radiofrequency devices work on the principle of Ohm law and are different from that of the photothermal effect produced by optical lasers. Radiofrequency leads to generation of heat due to natural resistance or impedance of the tissue to the movement of electrons within an RF field. The impedance varies with depth as well as with the type of tissue, such as skin, fat, and muscle. The effect of RF is 2-fold: initial immediate collagen contraction and a secondary wound-healing response, which involves collagen deposition and remodeling with tightening over time.<sup>3</sup>

Radiofrequency technology may be monopolar or bipolar. Monopolar RF application produces nonablative tissue tightening of the skin by volumetric heating of the deep dermis. Bipolar devices pass electrical currents between 2 positioned electrodes applied to the skin. It is believed that bipolar RF cannot produce uniform volumetric heating comparable with monopolar RF. Table 4 highlights an investigation of RF for the treatment of photodamage.<sup>3</sup>

Because RF is a new entry in the armamentarium of photoaging management, more research and experience are needed. Although not equivalent to results achieved by cosmetic surgeries, RF does offer a nonablative, noninvasive method of photorejuvenation with the advantages of very low downtime and potential complications.<sup>2</sup>

## CONCLUSION

Photodamage is defined as changes in the skin that occur after prolonged exposure to solar irradiation. Photoaging is one of the results seen with photodamage, which is an alteration in the skin caused by sun exposure resembling the effects of age. Skin cancers are at the other end of the spectrum of photodamage. UV radiation (UVR) is the common entity that contributes to both. The derangements in the epidermis and dermis mainly are attributable to collagen degradation and remodeling. These biologic processes translate to the clinical manifestations of photodamage, including wrinkles, decreased skin elasticity, hyperpigmentation, telangiectasias, actinic keratoses (AKs), and neoplasms. Sunscreens and antioxidants are photoprotective agents that aim to minimize the effects of UVR. The therapeutic modalities for the management of photodamage include topical agents, mechanical exfoliation, and laser therapies. Topical remedies such as retinoids,  $\alpha$ -hydroxy acids, and antioxidants commonly are used today. There is a wide gamut of laser and light devices, such as ablative lasers, nonablative lasers, fractional lasers, and radiofrequency ablation.



## REFERENCES

- [1]. Choudhary S, Jennifer C, Angel L et al. Photodamage, Part 1: Pathophysiology, Clinical Manifestations, and Photoprotection. *Cosmetic Dermatology*. 2010
- [2]. Choudhary S, Jennifer C, Angel L et al. Photodamage, Part 2: Management of Photoaging. *Cosmetic Dermatology*. 2010
- [3]. Burns JA. Thermage: monopolar radiofrequency. *Aesthet Surg J*. 2005;25:638-642.
- [4]. Gonzaga E. Role of UV Light in Photodamage, Skin Aging, and Skin Cancer. *Am J Clin Dermatol*. 2009;10:19-24
- [5]. Burke K. Photodamage of the skin: protection and reversal with topical antioxidants. *Journal of Cosmetic Dermatology* 2004;3:149-155
- [6]. Visscher M, Brian S, John K. Photodamage Treatments and Topicals for Facial Skin. *Facial Plast Surg Clin N Am*. 2013;21:61–75
- [7]. Chung JH, yanoK, Lee MK, et al. Differential effects of photoaging vs intrinsic aging on the vascularization of human skin. *Arch Dermatol* 2002; 138(11);1437-42
- [8]. Yaar M, Gilchrest BA. Aging of the skin. In : Freedberg IM, editor. *Fitzpatrick's dermatology in general medicine*. New York: McGraw-Hill, 2012: 1386-98
- [9]. Yadav N, Monisha Banerjee. Epidemiological Aspects of Photocarcinogenesis. *Photocarcinogenesis & Photoprotection*. 2018