



24TH WORLD CONGRESS
OF DERMATOLOGY
MILAN 2019



Proudly presented under
the auspices of the International
League of Dermatological Societies

This is to certify that the Abstract titled

CLASSIFICATION OF FOREIGN BODY REACTIONS DUE TO INDUSTRIAL SILICONE INJECTION

Ago Harlim ⁽¹⁾ - Mpu Kanoko ⁽²⁾ - Siti Aisah ⁽³⁾

*Medical Faculty, Christian University Of Indonesia, Department Of Dermatovenereology, Jakarta, Indonesia ⁽¹⁾ -
Medical Faculty, University Of Indonesia, Department Of Pathologic Anatomy, Jakarta, Indonesia ⁽²⁾ - Medical
Faculty, University Of Indonesia, Departement Of Dermatovenereology, Jakarta, Indonesia ⁽³⁾*

Has been presented **as e-Poster** during the 24th World Congress of Dermatology held in Milan from 10 to 15 June 2019.

Best regards,

Giovanni Pellacani, MD
President, WCD 2019

President: Giovanni Pellacani
Secretary-General: Ketty Peris

Organising secretariat
TriumphGroup

Via Lucilio, 60 - 00136 Rome, Italy
wcd2019milan@thetriumph.com

www.wcd2019milan.org





DERMATOLOGICAL SURGERY

CLASSIFICATION OF FOREIGN BODY REACTIONS DUE TO INDUSTRIAL SILICONE INJECTION

Ago Harlim⁽¹⁾ - Mpu Kanoko⁽²⁾ - Siti Aisah⁽³⁾

Medical Faculty, Christian University Of Indonesia, Department Of Dermatovenereology, Jakarta, Indonesia⁽¹⁾ - Medical Faculty, University Of Indonesia, Department Of Pathologic Anatomy, Jakarta, Indonesia⁽²⁾ - Medical Faculty, University Of Indonesia, Departement Of Dermatovenereology, Jakarta, Indonesia⁽³⁾

Background: Foreign-body reaction is a typical tissue response to a biomaterial that has been injected or implanted in human body tissue. There has been a lack of data on the classification of foreign body reaction to silicone injection, which can describe the pattern of body tissue responses to silicone.

Objective: We modified the classification proposed by Duranti et al, which has categorized a foreign-body reaction to hyaluronic acid injection into a new classification of a foreign-body reaction due to silicone injection.

Materials and method: A cohort study of 31 women suffering from silicone-induced granulomas on their chin was conducted. Granulomatous tissue and submental skin were stained with hematoxylin-eosin and evaluated.

Results: Our data revealed that there were at least seven categories of foreign body reactions to silicone injection could be developed. Categories 1-4 showed inflammatory activity, and categories 5-8 showed tissue repair by fibrosis.

Conclusion: With histopathological staining, we're able to sequence the steps of body reactions to silicone injection. Initial inflammatory reaction is then replaced by fibrosis process repairing the damaged tissues. The process depends on the host immune tolerance.

Level of Evidence: V, descriptive study

Keywords: Foreign-body reaction, Silicone, Granuloma



Classification of Foreign Body Reactions due to Industrial Silicone Injection

Ago Harlim, MD, MHA, PhD,^{1*} Mpu Kanoko, MD, PhD,² and Siti Aisah, MD, PhD³

¹Faculty of Medicine, Universitas Kristen Indonesia, Indonesia

²Faculty of Public Health, Universitas Diponegoro, Indonesia

³Faculty of Medicine, Universitas Indonesia, Indonesia

agoharlim@yahoo.com

Background

A foreign body reaction (FBR) is a typical tissue response to a biomaterial that has been injected or implanted in human body tissue. There has been a lack of data on the classification of foreign body reaction to silicone injection, which can describe the pattern of body tissue responses to silicone.

METHOD

We modified the classification proposed by Duranti and colleagues, which has categorized a FBR to hyaluronic acid injection into a new classification of an FBR to silicone injection. A cohort study of 31 women suffering from silicone-induced granulomas on their chin was conducted. Granulomatous tissue and sub-mental skin were stained with hematoxylineosin and evaluated.

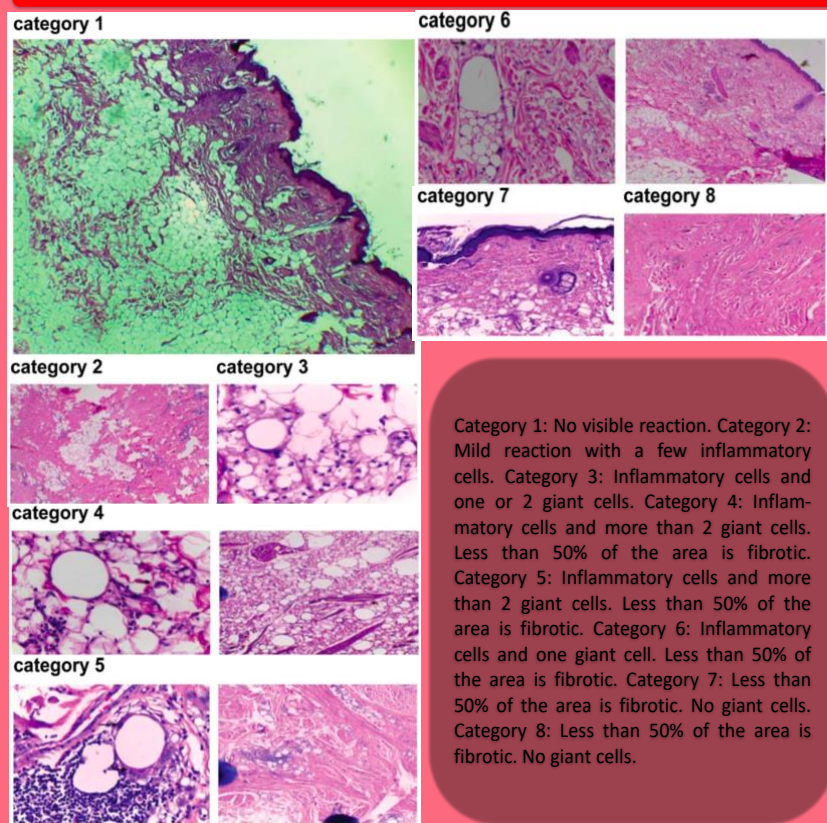
Result

Histopathological examination showed 8 categories of FBRs because of silicone injection. Those categories could be split into the following 7 stages without Category 1: Stage 1 (Category 2), mild reaction with few inflammatory cells; Stage 2 (Category 3), inflammatory cells with one or 2 giant cells; Stage 3 (Category 4), inflammatory cells with more than 2 giant cells and <50% of the area undergoing fibrosis; Stage 4 (Category 5), inflammatory cells with more than 2 giant cells and >50% of the area undergoing fibrosis; Stage 5 (Category 6), inflammatory cells with one giant cell and >50% of the area undergoing fibrosis; and Stage 6 (Category 7), <50% of the area now fibrotic with no giant cells; Stage 7 (Category 8), >50% of the area now fibrotic with no giant cells.

Conclusion

Using histopathological staining, we are able to sequence the steps of body reactions to silicone injection. Initial inflammatory reaction is then replaced by fibrosis process repairing the damaged tissues. The process depends on the host immune tolerance.

Figure 1. Categories of foreign body reactions to injected silicone.



Category 1: No visible reaction. Category 2: Mild reaction with a few inflammatory cells. Category 3: Inflammatory cells and one or 2 giant cells. Category 4: Inflammatory cells and more than 2 giant cells. Less than 50% of the area is fibrotic. Category 5: Inflammatory cells and more than 2 giant cells. Less than 50% of the area is fibrotic. Category 6: Inflammatory cells and one giant cell. Less than 50% of the area is fibrotic. Category 7: Less than 50% of the area is fibrotic. No giant cells. Category 8: Less than 50% of the area is fibrotic. No giant cells.

Table 1. Clinical Examination, Onset of Granuloma Symptoms, and Silicone Concentration for Subjects of Different Age Categories

Clinical Examination, Onset of Granuloma Symptoms, and Silicone Concentration for Subjects of Different Age Categories			
Variables	Normal Control Group (n=37)	Chin Granuloma Group (n=31)	Submental Skin Group (n=31)
Age (yr), X ± SD	47(28-55)	40.1 ± 8.78	40.1 ± 8.78
Clinical Examination, %			
Mild		6 (19.4%)	
Moderate		18 (58.1%)	
Severe		7 (22.6%)	
Onset of Granuloma Symptom (yr)		12.5 ± 5.5	12.5 ± 5.5
Silicone concentration (µg/g), median (minimum-maximum)	0 (0-253)	688 (4.1 - 10.430)	944 (0-6.065)

Table 2. Categories of Histopathology Examination in the Normal, Granuloma, and Submental Skin Group

Category	Normal (n = 37)	Granuloma (n = 31)	Submental Skin (n = 31)
	N	N	N
Category 1	13	0	0
Category 2	24	4	12
Category 3	0	10	9
Category 4	0	9	3
Category 5	0	4	2
Category 6	0	0	1
Category 7	0	2	1
Category 8	0	2	3

Table 3. Comparison of Histopathology Between the Granuloma and Submental Skin Group

Histopathology	Submental Skin		p
	Granuloma	Skin	
Category 1	0	0	p1 = .004*†
Category 2	4	12	r1 = 0.507
Category 3	10	9	R ² = 0.258
Category 4	9	3	
Category 5	4	2	
Category 6	0	1	
Category 7	2	1	
Category 8	2	3	

*Spearman test.

†p ≤ .05.

R², coefficient of determination.

Reference

- Senet P, Bachelez H, Ollivaud L, Vignon-Pennamen D, et al. Minocycline for treatment of cutaneous silicone granulomas. *Br J Dermatol* 1999;140:985.
- Lemperle G, Morhenn V, Charrier U. Human histology and persistence of various injectable filler substances for soft tissue augmentation. *Aesth Plast Surg* 2003;27:354-66.
- Anderson JM, Rodriguez A, Chang DT. Foreign body reactions to biomaterials. *Semin Immunol* 2008;20:86-100.
- Wick G, Grundtman C, Mayerl C, Wimpfissinger T, et al. The immunology of fibrosis. *Annu Rev Immunol* 2013;31:107-35.
- Tomazic-Jezic VJ, Merritt K, Umbreit TH. Significance of type and the size of biomaterial particles on phagocytosis and tissue distribution. *J Biomed Mater Res* 2001;55:523.

Classification of Silicone Foreign Body Reaction due to Industrial silicone injection

Ago Harlim
Universitas Kristen Indonesia

Introduction

Silicone injection has been used since 40 years ago and at that time, many problems occurred such as migration, inflammation, and granuloma. In 1992, FDA prohibited silicone injection for cosmetic use.¹ In addition to injection silicone may be introduced into our body or skin through food intake and cosmetic. Silicone has been widely used in daily cosmetics. Nowadays, due to technology advances, topical drugs can pass through skin barrier and can be penetrated into the skin, which has become a great concern as it may induce granuloma formation. There are relatively very few studies have been done on silicone concentration in normal skin.

A study conducted by A Harlim in 2018 found that normal skin contained silicone. The study was performed by taking skin samples from normal subjects and those with face-lift procedure and subsequently compared those samples using the same criteria with the control group, which included skin samples of subjects that had received silicone injection and the study found granuloma formation. The study found an average amount of silicone level of $44.07 \pm 75.86 \mu\text{g/g}$ in patients with normal skin; while in patients with granuloma, they found 38 times greater silicone level ($1709.21 \pm 1851.72 \mu\text{g/g}$).²

Silicone

Injectable-grade silicone for medical use has been manufactured widely since the element has been known for its stable and inert characteristics.^{5,6} It includes the use of silicone oil, which has been utilized in the treatment of complicated retinal detachment and heavy silicone oil tamponade. The treatment seems to offer promising results, particularly on improving visual acuity as well as great results on some anatomical parameters; however, there are some concerns as it may cause several complications such as cataract, increased ocular pressure, heavy silicon oil emulsification and mild inflammatory reaction.⁷⁻⁹

Injectable-grade silicone has also been widely used in the form of silicone oil injection. Some studies have suggested that it may have an essential role in reducing the risk of developing diabetic foot ulcer due to its pressure-reducing properties; therefore, it can maintain plantar tissue thickness and alleviate symptoms of diabetic foot ulcer, which may be associated with foot biomechanics.^{10,13}

Although it brings advantages, silicone injection may still develop some complications, either local or systemic complications. Local complications may include formation of palpable nodule surrounding injection site, arthralgia, fatigue, electrical neuropathy and electrical sensation;¹⁴ while systemic complications may also occur in the form of lymphadenopathy, renal disease and hepatic disease. It indicates that the injected silicone can migrate from injection site to other organ causing local and systemic complications. An animal experimental study in mice model may explain the pathogenesis of such complications. The study has demonstrated that macrophage of skin tissue may engulf the injected silicone and the silicone may be distributed through lymphatic circulation and ultimately causing accumulation in lymph nodes, adrenal glands, kidney, liver and spleen as well as granuloma formation in the skin.¹⁵ Complications due to silicone injection, particularly the granuloma formation may be dose-dependent. A study by A Harlim has demonstrated that granuloma formation could be developed when there is a large amount of silicone exposure as the study only found a low level of silicone without any granuloma formation in normal skin.²

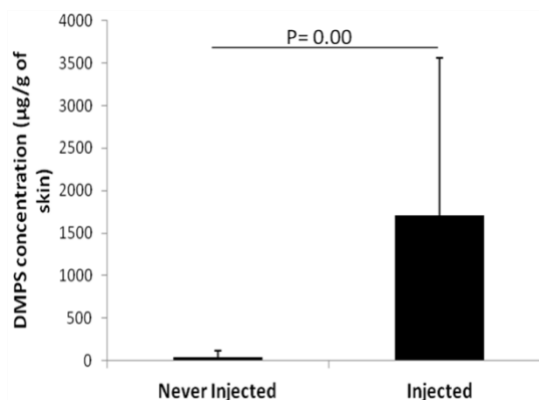


Figure 1. The level of silicon (Si) in normal subjects who had never received silicone injection (never injected) and in subjects with granuloma who had received silicone injection (injected)

Cultural changes have been encouraging people to pursue their passion on beauty and youth; therefore, cosmetology has been rapidly growing. With technological advances, more mixed drug ingredients have been added to cosmetic products in order to beautify their customers. Thus, it may indirectly increase the use of topical

cosmetics that usually contain silicone; therefore, it will lead to increase silicone uptake to the skin. It has raised a concern that prolonged and continuous use of cosmetics will cause granuloma formation and other chronic inflammatory effects.

Dietary intake and silicon

Aside from medical use, silicon has also been used in food industry, cosmetics and pharmaceutical industries. Our data shows that the silicon levels in gastrointestinal medications (e.g. antacids), mineral water and soda drinks are 44.1, 25.6, 2.91 µg/g, respectively. It can be said that there are many routes for administering silicon into our body. The average daily intake of silicon for European and North American populations is 20-50 mg/day. In China and India, the daily intake of silicon is larger that may reach as many as 140-200 mg/day, in which wheats, fruits and vegetables are the greatest producers.³

A research institution of healthy aging and nutrition in U.K. has recently reported a strong correlation between silicon in dietary intake and the health of bone and connective tissue. Therefore, it can be assumed that the correlation is associated with collagen synthesis and/or stabilization of mineral matrix, i.e. silicone intake may affect bone density.⁴

Another study, which is an animal experimental study, has demonstrated that there is no evidence of silicon accumulation in silicon consumption. Silicon can be eliminated through digestion process and can be found feces (93-97%), urine (0.001-0.22%) and expired air (0.01-0.02%).⁵ It indicates that silicon is a stable element and at certain degree it can be resistant to digestive enzymes including gastric acid; therefore, it seems that silicon is not accumulated in the gastrointestinal system.

Silicon in Cosmetics

Beauty products for face, hair, and cosmetics may have high silicon content, in which it will be accumulated in the skin tissue. When a topical beauty product containing silicon is applied to the skin, the elastometric particles of silicon will absorb various liquids including emollient and oil; therefore, silicon is used in skin care product as vehicle (carrier) of active ingredient for the skin or as oil control product of the skin.^{6,7}

Types of silicone that are commonly used in cosmetic products:

- Dimethicone – clear, inert, liquid solubility depends on the length of polymer backbone ranging in thickness from watery consistency to thick.

- Dimethicone Copolyol – silicone that contains an –OH group; therefore it is more water soluble resulting in easier incorporation into water-based formulations and also reduces the “slip effect” of the silicone
- Cyclomethicone – the shortest cyclic molecule, which has many similarities with dimethicone except it can evaporate; while dimethicone can not.
- Cyclo-Dimethicone – a combination of dimethicone dan cyclomethicones.

The great use of silicones in cosmetic product may increase the risk of accumulation of the substance in our body, particularly in facial skin. No clear evidence has been found on the bioavailability and concentration of accumulated silicone in topical uses.

Granuloma: Definition

Granuloma is a foreign body reaction against foreign substances that enter the skin. Granuloma occurs due to continuous or chronic inflammation against foreign substances. Silicone is a foreign substance in the body, which will be encapsulated by the body. Datia cells (giant cells) will encapsulate silicone material and therefore; inflammatory mediators can not perform phagocytosis, which result in continuous inflammation and causes side effect. The encapsulated material has poor vascularization; therefore it may potentially induce infections.⁸

Classification and Etiology

There are many kinds of granuloma classification; however, the common classifications are those which have been adjusted to the etiologies.^{9,10} Granuloma formation may occur due to various factors such as biologic, chemical and physical irritative agents.⁹ Classification based on clinical, ethiological, histopathological features can be categorized further into infection, vasculitis, immunological aberration, leukocyte oxidation deficiency, hypersensitivity, chemicals or neoplasma.^{11,12} Table 2.2 presents classification of granuloma based on etiology.¹⁰

Table 1 Classification of granulomatous disorders (Cited from: James DG, Williams WL).¹⁰

===== ===== Infections	Immunological aberration
===== ===== Fungi	Sarcoidosis
Histoplasma	Crohn’s disease
Coccidioides	Phimary billiary cirrhosis

Blastomyces
Sporothrix
Aspergillus
Cryptococcus

Protozoa

Interferon-8-receptor deficiency
Toxoplasma
Leishmania

Metazoa

Toxocara
Schistosoma

Spirochaetes

T. Pailidum
T. carateum
T. pertunue

Mycobacteria

M. tuberculosis
M. leprae
M. kansasil
M. marinum
M. avian
BOG vaccine

Bacteria

Brucella
Yersinia

Other infections

Cat-scratch
Lymphogranuloma

Neoplasia

Carcinoma
Reticulosis
Pinealoma
Dysgerminoma
Seminoma
Reticulum cell sarcoma
Reticulum cell sarcoma
Malignant nasal granuloma

Chemicals

Beryllium
Zirconium
Silica

Glant cell arteritis
Peyronie's disease
Hypogammagiobulinaemia
Langerhans' granulomatosis
Hepatic granulomatous disease

Immune complex disease

Vasculitic granulomatosis

Wegener's
Necrotizing sarcoidal
Churg-Strauss
Lymphomatoid
Polyarteritis nodosa
Bronchocentric
Systemic lupus

Leukocyte cocidase defect

Chonic granulomatous
disease of childhood

Hypersensitivity pneumonitis

Farmers' lung
Bird fanciers'
Mushroom workers'
Suberosis (cork dust)
Bagassosis
Marple bark strippers'
Paprika splitters'
Coffee bean
Spatlese lung

Other

Fibrosing alveolitis
Whipple's disease
Pyrexia of unknown origin
Radiotherapy
Cancer chemotherapy
Panniculitis
Chalazion
Sebaceous cyst
Dermoid
Sea urchin spine injury
Tattoo
Malakoplakia
Blau's syndrome

Silicone granuloma

Silicone granuloma is a foreign-body granuloma, which is characterized by the presence of multinuclear giant cells and macrophages surrounded by lymphocytes and infiltrates of neutrophils. The granulomatous histological lesion caused by silicone varies depending on the type of silicone.

Tissue reactions to silicone gel or liquids is characterized by the formation of silicone granuloma with cystic space containing foreign body.¹³ The irregular surface of silicone can not be phagocytosed completely by macrophage. Giant cells are formed due to “frustrated” macrophages. Microspheres in the size of less than 15 microns will be phagocytosed and transferred to lymph node; while those with big size and non-absorbable polymer will be encapsulated by fibrotic tissue.¹⁴

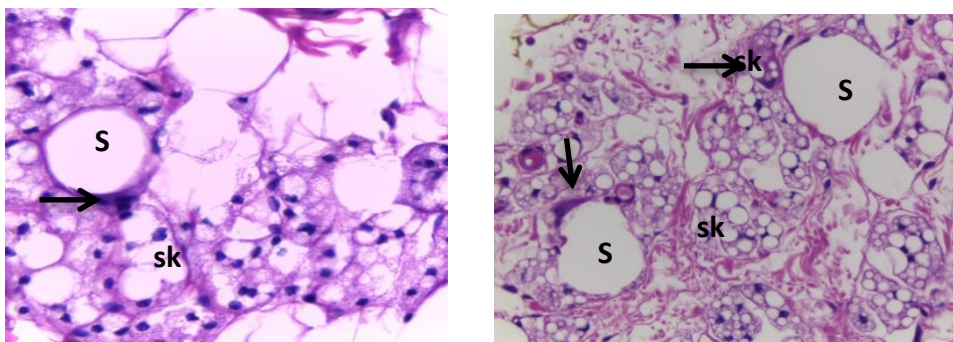


Figure 2. Results of histopathological examination (HE 400x magnification) in one of study subject. There is a giant cell (arrow), which is phagocytosing silicone (S) and is trying to destruct it into smaller pieces (sk).¹

Giant cell is essential in tissue response to silicone as seen in figure 2, in which the giant cell is phagocytosing the silicone. It appears that although the giant cell can not eliminate the silicone, but it would produce fragmented silicone into smaller pieces. Within a month, the silicone will be in the size of 20-100 microns.¹⁵ However, it still can not be completely phagocytosed and ultimately it will be encapsulated by fibrotic tissue.

In general, silicone granuloma can be categorized into 3 phases according to the natural history of our immune response, which are mild inflammatory phase, i.e. stage 1; inflammation with giant cells, i.e. stage 2, 3, 4, 5 and tolerance phase with fibrosis, i.e. stage 6 and 7.

According to A Harlim in 2018, histopathological features of silicone granuloma can be categorized into 7 stages, which are:¹⁵

Stadium 1, Moderate reaction with a few inflammatory cells

Stadium 2, Inflammatory cells with one or two giant cell(s)

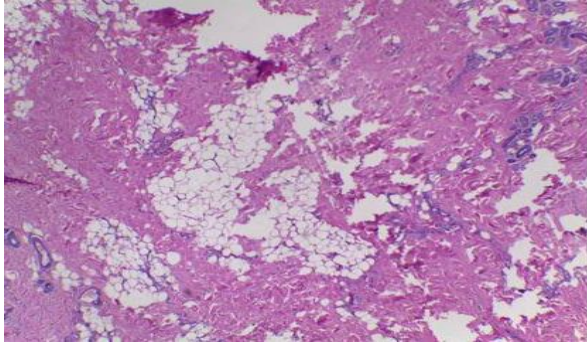
Stadium 3, Inflammatory cells with more than two giant cells and < 50% fibrotic area

Stadium 4, Inflammatory cells with more than two datia cells and > 50% fibrotic area

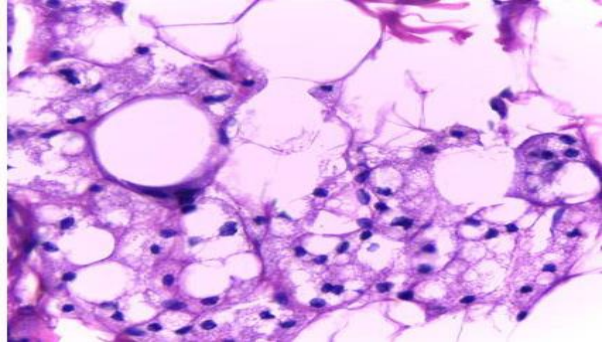
Stadium 5, Inflammatory cells with one datia cell and > 50% fibrotic area

Stadium 6, < 50% fibrotic area with no datia cell

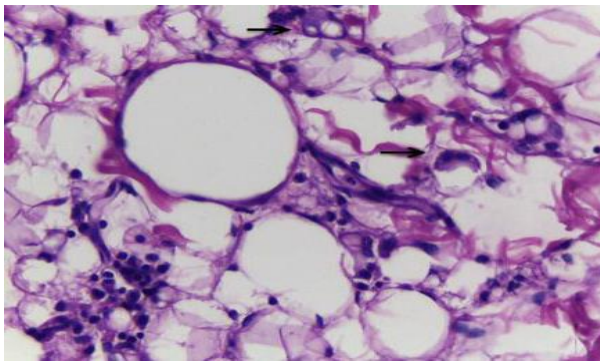
Stadium 7, > 50% fibrotic area with no datia cell



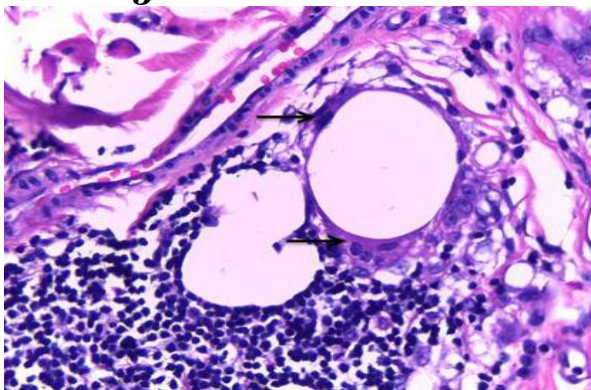
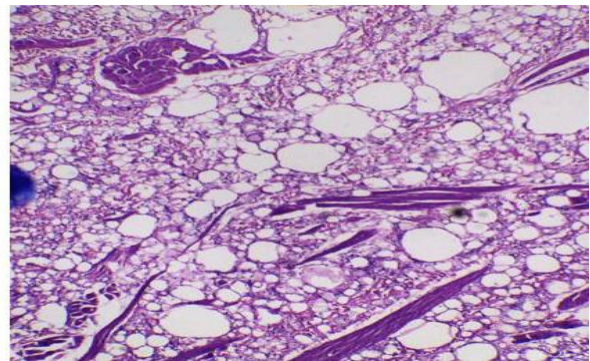
Stadium 1



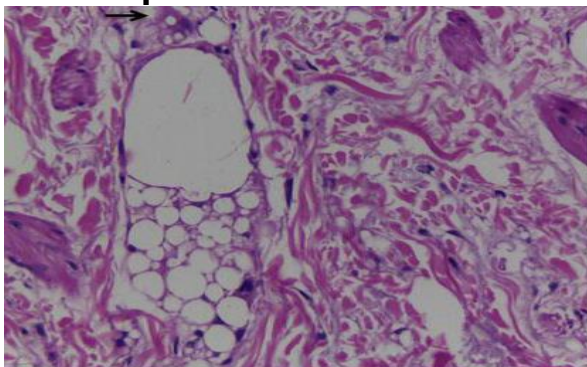
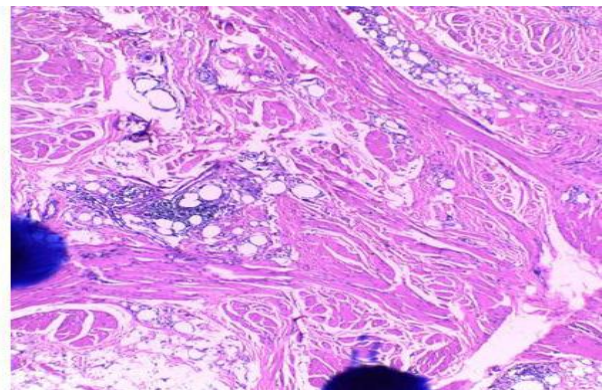
Stadium 2



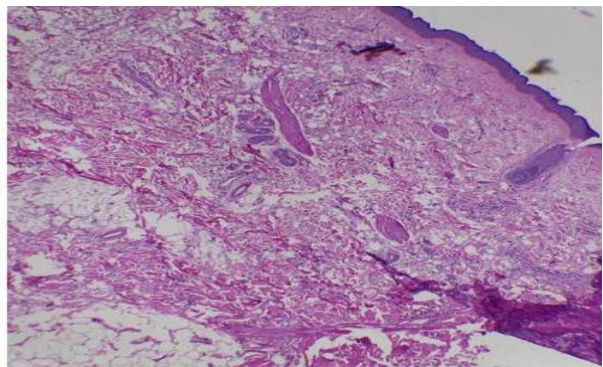
Stadium 3

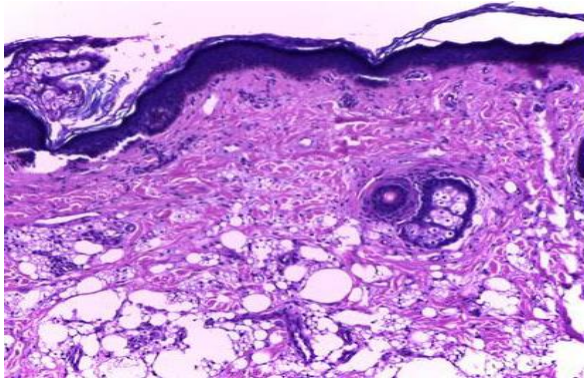


Stadium 4

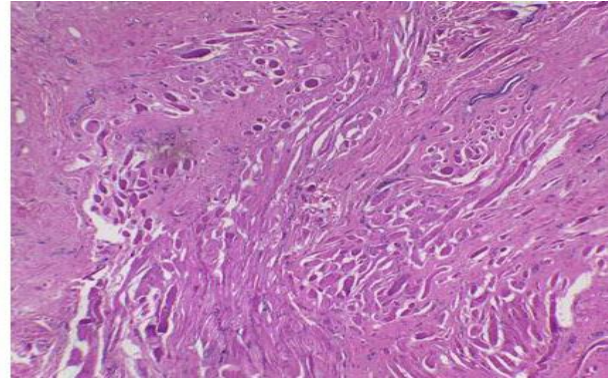


Stadium 5





Stadium 6



Stadium 7

Figure 3. Stadium 1, Moderate reaction with a few inflammatory cells. Stadium 2, Inflammatory cells with one or two datia cell(s). Stadium 3, Inflammatory cells with more than two datia cells and < 50% fibrotic area. Stadium 4, Inflammatory cells with more than two datia cells and > 50% fibrotic area. Stadium 5, Inflammatory cells with one datia cell and > 50% fibrotic area. Stadium 6, < 50% fibrotic area with no datia cell. Stadium 7, > 50% fibrotic area with no datia cell.

Diagnosis

Granuloma is a form of localized nodular inflammation, which is found in tissues.⁹ On examination, there is a tumor-like mass or node of granulation tissue with active fibroblast growth and capillaries that contain epithelial-like macrophages surrounded by mononuclear cells, lymphocytes, and sometime multinucleated datia cells present at the central core of granuloma.¹⁶

On clinical point of view, silicone granuloma is characterized by the presence of complications of silicone. There are usually granuloma nodes, migrating silicone, wider nose and signs of inflammation such as redness and swelling depending on the stage.

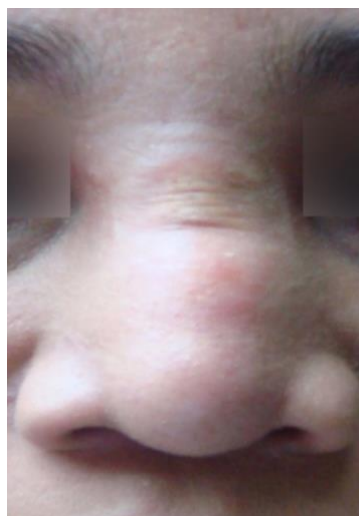

Figure 4. Granuloma due to nasal silicone injection. On the photograph, there is granuloma node, migrating silicone, the nose becomes wider and signs of inflammation such as edema and redness.

REFERENCES

1. Peters W, Fomarsier V. Complication from injectable material used for breast augmentation. *Can J Plastic Surgery*. Autumn 2009; 17(3). Tersedia di: <http://www.ncbi.nlm.nih.gov/june/article/PMC740603>. Diunduh 16 Oktober 2010.
2. Harlim A, Aisah S, Sihombing R. Silikon Level in Skin Tissues of Normal Female Individuals. *Journal of Pakistan aassociation of Dermatologists* 2018; (28)2
3. C. T. Price, K. J. Koval, J. R. Langford. Review Article Silikon: A Review of Its Potential Role in the Prevention and Treatment of Postmenopausal Osteoporosis. Hindawi Publishing Corporation *International Journal of Endocrinology*. Vol 2013.
4. R. Jugdaohsingh. Silikon And Bone Health. *J Nutr Health Aging*. Europe PMC Funders Group. 2007; 11(2): 99-110.
5. Eighteenth Report of the Joint FAO/WHO Expert Committee on Food Additives, Wld Hlth Org. techn. Rep. Ser., 1974, No. 557. FAO Nutrition Meetings Report Series, 1974, No. 54. <http://www.inchem.org/documents/jecfa/jecmono/v06je42.htm>
6. D.T. Liles, F. Lin. Silikon Elastomeric Particles in Skin Care Applications. Science & Technology Department. 2010. Vol 1053. Chapter 11. Pp 207-219.
7. Nair A, Jacob S, Al-DhUBLab B, Attimarad M, Harsha S. Basic considerations in the dermatokinetics of topical formulations. *Brazilian Journal of Pharmaceuticals Sciences*. 2013; 40(2): 423-434
8. Silikon Laboratory. Liquid silikon injection. Tersedia di: http://www.yestheyrefake.net/liquid_silikon_risks.htm. Diunduh 11 Agustus 2010.
9. Granuloma. Medterms Online Medical Dictionary. [Internet]. 1998 [cited 2011 Mar 20]. Tersedia di: <http://medterms.com>.
10. James DG, Williams WL. Classification of granulomatous disorders: a clinicopathological synthesis. Dalam: James DG, Zumla A.ed. *Granulomatous disorders*. United Kingdom: Cambridge press; 1999.p.17-27.
11. James DG. A Clinicopathological Classification of Granulomatous Disorders. *Postgrad Med J*. 2000;76(898):457-65.
12. Agustini C, Semenzato G. Biology and immunology of granuloma. Dalam: James DG, Zumla A ed. *Granulomatous disorders*. United Kindom: Cambridge press; 1999.p.3-16.
13. Bondurant S, Ernster V, Herdman R. Antinuclear antibodies and silikon breast implantts. Dalam: *Safety of Silikon Breast Implants*. Washington: The National Academy Press;1999.h.198-214.
14. Lemperle G, Morhenn V, Charrier U. Human histology and persistence of various injectable filler substances for soft tissue augmentation. *Aesth Plast Surg*. 2003;27:354-66. Doi:10.1007/s00266-003-3022-1.
15. Harlim A, Kanoko M, Aisah S. Classification of foriegn body reaction duet o industrial silikon injection. *Dermatologic surgery journal*.2018 ;(44)9:1174-82
16. Granuloma. *Dorland's Medical Dictionary*. [Internet]. Saunders & Elsevier; 2007 [cited 2011 Apr 13]. Tersedia di: <http://www.medical-dictionary.thefreedictionary.com>.
17. Pollack SV. Wound healing: a review . IV. Systemic medications affecting wound healing. *J Dermatol Surg Oncol* 1982;8:667-72.
18. Adams C, Ratner D. Composite and free cartilage grafting. *Dermatol Clin* 2005;23:129-40, vii.

19. Kovich O, Otley CC. Thrombotic complications related to discontinuation of warfarin and aspirin therapy perioperatively for cutaneous operation. *J Am Acad Dermatol* 2003;48:233-7.
20. Sheen JH, Sheen AP. *Aesthetic Rhinoplasty*, 2nd ed. St Louis: Quality Medical Publishing, 1998.
21. Tardy ME. *Rhinoplasty: The Art and the Science*. Philadelphia: WB Saunders, 1997.
22. Buku *asthetic surgery*
23. Ellis LZ, Cohen JL, High W. Granulomatous reaction to silikon injection. *J Clin Aesthet Deramatol.* 2012;5(7);44-7. Aavailable at <http://www.ncbi.nlm.nih.gov/pmc/articles/PMC3396457/>. Diunduh 8 Desember 2014.
24. Arin MJ, Bate J, Krieg T, Hunzelmann N. Silikon granuloma of face treated with minocycline. *JAAD.* 2005;52(2): S53-6.